Update of the international multidisciplinary classification of the interstitial pneumonias: an ERS/ATS statement

Christopher J. Ryerson[1,42], Ayodeji Adegunsoye[2,42], Sara Piciucchi[3,4,42], Lida P. Hariri[5], Yet H. Khor[6,7,8,9], Marlies S. Wijsenbeek[10], Athol U. Wells[11], Amita Sharma[12], Wendy A. Cooper[13], Katerina Antoniou[14], Raphael Borie[15], Aurelie Fabre[16,17], Yoshikazu Inoue[18,19], Kerri Johannson[20], Takeshi Johkoh[21], Leticia Kawano-Dourado[22,23,24], Ella Kazerooni[25], Toby M. Maher[26,27], Philip L. Molyneaux[27,28], Raymond Protti[29], Claudia Ravaglia[3,30], Elisabetta A. Renzoni[27,31], Ryoko Saito-Koyama[32], Nicola Sverzellati[33,34], Simon L.F. Walsh[35,36,37], Paul Wolters[38], Soo-Ryum Yang[39], William Travis[40,42] and Andrew G. Nicholson[27,41,42]

[1]Department of Medicine and Centre for Heart Lung Innovation, University of British Columbia, Vancouver, BC, Canada. [2]Department of Medicine, Section of Pulmonary and Critical Care, University of Chicago, Chicago, IL, USA. [3]Department of Medical and Surgical Sciences (DIMEC), University of Bologna, Bologna, Italy. [4]Department of Radiology, G.B. Morgagni-Pierantoni Hospital, Forlì, Italy. [5]Department of Pathology and Division of Pulmonary and Critical Care Medicine, Massachusetts General Hospital, Harvard Medical School, Boston, MA, USA. [6]Respiratory Research@Alfred, School of Translational Medicine, Monash University, Melbourne, Australia. [7]Department of Respiratory and Sleep Medicine, Austin Health, Heidelberg, Australia. [8]Institute for Breathing and Sleep, Heidelberg, Australia. [9]Faculty of Medicine, University of Melbourne, Melbourne, Australia. [10]Centre of Expertise for Interstitial Lung Diseases and Sarcoidosis, Department of Respiratory Medicine, Erasmus MC, Rotterdam, The Netherlands. [11]Interstitial Lung Disease Unit, Royal Brompton Hospital and Imperial College, London, UK. [12]Department of Radiology, Massachusetts General Hospital, Harvard Medical School, Boston, MA, USA. [13]Tissue Pathology and Diagnostic Oncology, NSW Health Pathology, Royal Prince Alfred Hospital, Camperdown, Australia. [14]Dept of Respiratory Medicine, Laboratory of Molecular and Cellular Pneumonology, School of Medicine, University of Crete, Heraklion, Greece. [15]Université Paris Cité, Inserm, PHERE, Hôpital Bichat, AP-HP, Service de Pneumologie A, Centre Constitutif du Centre de Référence des Maladies Pulmonaires Rares, FHU APOLLO, Paris, France. [16]Histopathology Dept, St Vincent's University Hospital, Dublin, Ireland. [17]University College Dublin School of Medicine, Dublin, Ireland. [18]Clinical Research Center, NHO Kinki Chuo Chest Medical Center, Osaka, Japan. [19]Department of Internal Medicine, Osaka Anti-tuberculosis Association, Osaka Fukujuji Hospital, Osaka, Japan. [20]Department of Medicine and Snyder Institute for Chronic Diseases, University of Calgary, Calgary, AB, Canada. [21]Department of Radiology, Kansai Rosai Hospital, Amagasaki, Japan. [22]Hcor Research Institute, Hcor Hospital, Sao Paulo, Brazil. [23]MAGIC Evidence Ecosystem Foundation, Oslo, Norway. [24]Pulmonary Division, Heart Institute (InCor), University of Sao Paulo, Sao Paulo, Brazil. [25]Departments of Radiology and Internal Medicine, University of Michigan, Ann Arbor, MI, USA. [26]Keck School of Medicine, University of Southern California, Los Angeles, CA, USA. [27]National Heart and Lung Institute, Imperial College London, London, UK. [28]Royal Brompton and Harefield Hospitals, Guy's and St Thomas' NHS Foundation Trust, London, UK. [29]Patient representative. [30]Pulmonology Unit, G.B. Morgagni Hospital, Forlì, Italy. [31]Interstitial Lung Disease Unit, Royal Brompton and Harefield Hospitals, Guy's and St Thomas' NHS Foundation Trust, London, UK. [32]Department of Pathology, National Hospital Organization, Sendai Medical Center, Miyagi, Japan. [33]Department of Medicine and Surgery, University of Parma, Parma, Italy. [34]Scienze Radiologiche, University Hospital of Parma, Parma, Italy. [35]Department of Radiology, Imperial College, London, UK. [36]Department of Radiology, Royal Brompton and Harefield Foundation Trust, London, UK. [37]Qureight Ltd, Cambridge, UK. [38]Department of Medicine, Division of Pulmonary, Critical Care, Allergy and Sleep Medicine, University of California, San Francisco, CA, USA. [39]Department of Pathology and Laboratory Medicine, Memorial Sloan Kettering Cancer Center, New York, NY, USA. [40]Dept of Pathology, Memorial Sloan Kettering Cancer Center, New York, NY, USA. [41]Department of Histopathology, Royal Brompton and Harefield Hospitals, Guy's and St Thomas' NHS Foundation Trust, London, UK. [42]Contributed equally.

Corresponding author: Christopher J. Ryerson (chris.ryerson@hli.ubc.ca)

Shareable abstract (@ERSpublications)
This update builds upon the previous classification approach by describing major advances in the classification of interstitial pneumonia over the past decade https://bit.ly/41oWvZl

Cite this article as: Ryerson CJ, Adegunsoye A, Piciucchi S, *et al*. Update of the international multidisciplinary classification of the interstitial pneumonias: an ERS/ATS statement. *Eur Respir J* 2025; 66: 2500158 [DOI: 10.1183/13993003.00158-2025].

Copyright ©The authors 2025.

Abstract

Background The 2013 American Thoracic Society/European Respiratory Society statement on the classification of the idiopathic interstitial pneumonias described six major and two rare subtypes of idiopathic interstitial pneumonia, as well as recognising unclassifiable disease.

Downloaded from https://publications.ersnet.org on October 19, 2026 by guest. Please see licensing information on first page for reuse rights.

For reproduction rights and permissions contact permissions@ersnet.org

This article has an editorial commentary: https://doi.org/10.1183/13993003.01845-2025

Received: 29 Jan 2025
Accepted: 14 June 2025

Objective The objective of this statement is to update the 2013 classification of interstitial pneumonia.
Methods Five co-chairs identified a committee of 32 experts in the field, as well as two individuals with lived experience. Creation of the document was supported by a series of video meetings, first including the full committee and then subgroups assigned to draft specific sections of the document. The classification scheme was developed by consensus.
Results The multidisciplinary committee of experts identified four major advances to the classification of interstitial pneumonia: 1) expansion beyond idiopathic interstitial pneumonias to also include secondary causes; 2) identification of new subcategories and updated terms, including addition of bronchiolocentric interstitial pneumonia as a major pattern as well as changing from acute interstitial pneumonia to idiopathic diffuse alveolar damage and desquamative interstitial pneumonia to alveolar macrophage pneumonia; 3) subclassification of interstitial and alveolar filling disorders, with interstitial disorders further subclassified as fibrotic *versus* non-fibrotic; and 4) consideration of diagnostic confidence in patient evaluation and management. The committee also provided a comprehensive update on the status of potential molecular tools and identified future research priorities.
Conclusions This update builds upon the previous classification approach by describing major advances in the classification of interstitial pneumonia over the past decade.

Background

Interstitial pneumonia is an umbrella term for ~200 rare diseases that primarily affect the interstitium and/or small airways and alveoli. The 2002 American Thoracic Society/European Respiratory Society classification of the idiopathic interstitial pneumonias defined seven specific entities using standardised terminology, with a multidisciplinary gold standard for diagnosis [1]. This was updated in 2013 with formal recognition of nonspecific interstitial pneumonia (NSIP) as a major pattern, addition of pleuroparenchymal fibroelastosis (PPFE) as an eighth entity, documentation of additional histological patterns, increased recognition of mixed patterns of lung injury (*e.g.* acute exacerbations of idiopathic interstitial pneumonia), greater recognition of the importance of disease behaviour, and review of potential molecular markers [2]. This new document aims to update the classification of the interstitial pneumonias, now including both idiopathic and secondary causes of interstitial pneumonia, with the goal to improve patient care and support further research in this challenging area. We focus on the increased understanding of secondary and idiopathic interstitial pneumonia, advances in molecular pathology, and recognition of progressive pulmonary fibrosis (PPF) as a framework relevant to currently available pharmacotherapies [3, 4].

While we maintain the term “interstitial pneumonia” (without “idiopathic”) throughout this document, the term “interstitial lung disease” (ILD) can also be used to refer to these disorders and is retained as the root term for some specific diagnoses. Despite some limitations, the committee preferred the term “interstitial pneumonia” to maintain continuity with the 2002 and 2013 documents on this topic and to better include alveolar filling disorders (*i.e.* “pneumonias”). Some lung conditions that affect the pulmonary interstitium are not comprehensively addressed in this document, including pneumoconioses, small airways diseases, pulmonary vascular disorders, sarcoidosis, alveolar haemorrhage syndromes, effects of transplantation, lung disorders in immunocompromised patients, primary pulmonary infections, histiocytic disorders such as Langerhans cell histiocytosis and Erdheim–Chester disease, lymphangioleiomyomatosis, and inhalational injury. The committee had interest in addressing interstitial pneumonia with autoimmune features within this statement, but it was determined that this topic required a dedicated document to address it properly. Furthermore, we do not comprehensively address management.

Methodology

The co-chairs identified a committee of 32 experts in the field as well as two individuals with lived experience. The committee was selected to represent a diversity of clinical expertise, geography, gender, race, and seniority, although with some imbalances and the potential for similar views among some committee members who have worked together previously. All participants disclosed industry relationships at the beginning of the project, which were deemed to not be relevant to the content of the final document. Creation of this document was supported by a series of video meetings, first including the full committee and then subgroups assigned to draft specific sections of the document. Due to the broad nature of the topic, we decided to not search systematically to identify literature, but rather to include literature based on expert consensus. The classification scheme was therefore developed by consensus, with discussions focused on the participants’ clinical experience and general clinical knowledge, rather than a formal evidence synthesis. Decisions were made using consensus by discussion. When it was unclear whether there was consensus, voting was employed, with 70% agreement necessary for consensus. To mitigate the likelihood that evidence would be selected to support predetermined beliefs (*i.e.* cherry-picking), the co-chairs composed a committee known to have a variety of different perspectives on the topic and every committee member was encouraged to select, review, and discuss the relevant literature. The literature that

Downloaded from https://publications.ersnet.org on October 19, 2026 by guest. Please see licensing information on first page for reuse rights.

informed discussion and consensus was identified by nonsystematic searches and awareness of key studies by the expert committee members.

Classification approach

Overview of 2013 classification schema

The 2013 classification primarily categorised patients according to histological pattern, including six "major" idiopathic interstitial pneumonias, two "rare" idiopathic interstitial pneumonias, and unclassifiable idiopathic interstitial pneumonia [2]. Important differential diagnoses were discussed, but not considered within the category of idiopathic interstitial pneumonia, given their known causes (*e.g.* fibrotic hypersensitivity pneumonitis (HP), connective tissue disease-associated ILD (CTD-ILD)). The major idiopathic interstitial pneumonias were further subclassified as chronic fibrosing, smoking-related, and acute/subacute. A complementary disease behaviour approach based on anticipated clinical trajectory was also described, alongside suggested monitoring and treatment implications.

New classification schema and rationale for major changes

The updated approach to interstitial pneumonia classification is shown in table 1, figure 1 and supplementary table S1, again focusing the stratification of patients initially by major histological and radiological patterns. This approach continues to emphasise the distinction between pattern and multidisciplinary diagnosis (*e.g.* "NSIP" is a pattern while "idiopathic NSIP" is a multidisciplinary diagnosis). Significant changes compared to 2002 and 2013 are presented in figure 2. The updated classification of the interstitial pneumonias includes four major changes, as follows.

Expansion beyond idiopathic interstitial pneumonias

The 2002 and 2013 documents addressing the classification of the interstitial pneumonias focused on idiopathic entities [1, 2]; however, there is no longer clear justification for separating idiopathic from

TABLE 1 Morphological patterns of interstitial and alveolar filling disorders and associated clinical-radiological-pathological diagnoses. Secondary aetiologies are listed before primary/idiopathic aetiologies to emphasise the importance of excluding an underlying cause before considering a diagnosis to be primary/idiopathic

Morphological patterns by pathology and imaging	Major clinical-radiological-pathological diagnoses	
	Secondary	Primary/idiopathic
Interstitial patterns		
UIP	Secondary UIP (*e.g.* CTD, HP, medications)	IPF (idiopathic UIP)
NSIP	Secondary NSIP (*e.g.* CTD >>> HP, medications)	Idiopathic NSIP
BIP[#]	Secondary BIP (*e.g.* HP >>> CTD, aspiration, inhalational exposures, medications)	Idiopathic BIP (provisional diagnosis[#])
DAD	Secondary DAD (multiple causes)	Idiopathic DAD (acute interstitial pneumonia)
PPFE	Secondary PPFE (*e.g.* IPF, CTD, HP, medications, radiation, transplant (restrictive allograft syndrome, pulmonary infection (post-tuberculosis), occupational)	Idiopathic PPFE
LIP	Secondary LIP (*e.g.* CTD, immune deficiency)	Idiopathic LIP
Alveolar filling patterns		
Organising pneumonia	Secondary organising pneumonia (*e.g.* CTD, post-infectious, medications, aspiration)	Cryptogenic organising pneumonia (idiopathic organising pneumonia)
RB-ILD	Secondary RB-ILD (*e.g.* smoking >>> CTD, medications, aspiration, hereditary)	Idiopathic RB-ILD
AMP[¶]	Secondary AMP (*e.g.* smoking >>> CTD, medications, aspiration, hereditary	Idiopathic AMP
Rare alveolar filling disorders	*e.g.* Acute and chronic eosinophilic pneumonia, pulmonary alveolar proteinosis, lipoid pneumonia (supplementary table S1)	
Other		
Combined pattern	Multiple combinations (*e.g.* NSIP + organising pneumonia, UIP + PPFE)	
Unclassifiable pattern	Unclassifiable ILD (multiple undefined patterns)	

UIP: usual interstitial pneumonia; NSIP: nonspecific interstitial pneumonia; BIP: bronchiolocentric interstitial pneumonia; DAD: diffuse alveolar damage; PPFE: pleuroparenchymal fibroelastosis; LIP: lymphoid interstitial pneumonia; RB-ILD: respiratory bronchiolitis-interstitial lung disease; AMP: alveolar macrophage pneumonia; CTD: connective tissue disease; HP: hypersensitivity pneumonitis; IPF: idiopathic pulmonary fibrosis. [#]: the committee voted 29 to four (88% to 12%) in favour of including BIP as a pattern and 27 to six (82% to 18%) in favour of introducing idiopathic BIP as a provisional multidisciplinary diagnosis; [¶]: formerly referred to as desquamative interstitial pneumonia.

Downloaded from https://publications.ersnet.org on October 19, 2026 by guest. Please see licensing information on first page for reuse rights.

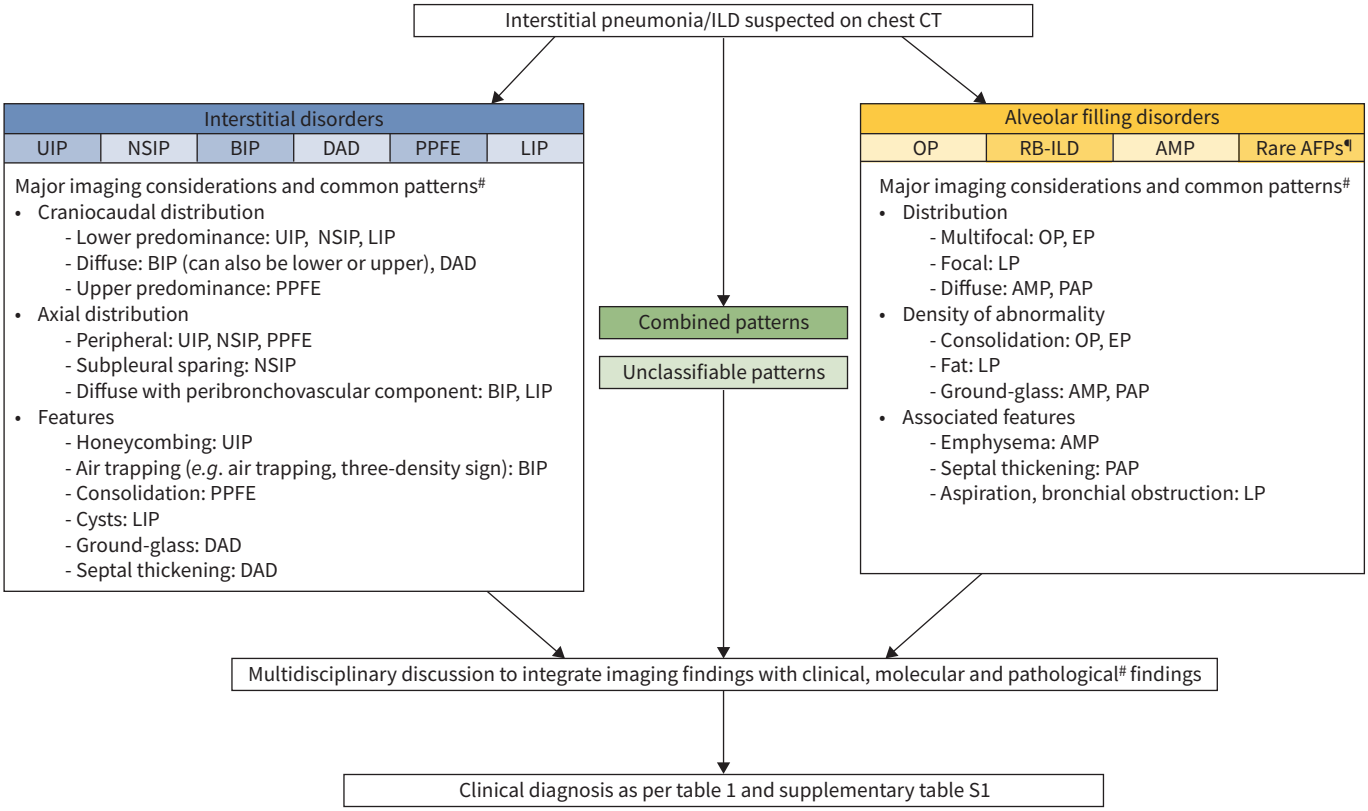

FIGURE 1 Classification schema overview. ILD: interstitial lung disease; CT: computed tomography; UIP: usual interstitial pneumonia; NSIP: nonspecific interstitial pneumonia; BIP: bronchiolocentric interstitial pneumonia; DAD: diffuse alveolar damage; PPFE: pleuroparenchymal fibroelastosis; LIP: lymphoid interstitial pneumonia; OP: organising pneumonia; RB: respiratory bronchiolitis; AMP: alveolar macrophage pneumonia; AFP: alveolar filling pattern; EP: eosinophilic pneumonia; LP: lipoid pneumonia; PAP: pulmonary alveolar proteinosis. #: imaging and pathological features are described in more detail in table 2 and supplementary table S2; ¶: rare AFPs include acute and chronic EP, PAP, LP and others.

non-idiopathic (secondary) causes and we therefore present a single classification system that incorporates all interstitial pneumonias. While there remains clinical relevance to identifying the underlying cause of a given pattern, this approach acknowledges that aetiology is unclear at initial presentation for many cases. In addition, some of these diagnoses were seldom considered idiopathic (*e.g.* respiratory bronchiolitis-associated ILD), and even those still termed idiopathic (*e.g.* idiopathic pulmonary fibrosis (IPF)) may have underlying causes [5, 6]. This classification approach is intentionally structured such that newly identified causes can easily be added to the list of secondary disorders associated with each pattern, facilitating further updates to classification and terminology as more is learnt about these diseases.

New subcategories and terms: bronchiolocentric interstitial pneumonia, alveolar macrophage pneumonia, and idiopathic diffuse alveolar damage

Although most patterns described in the 2013 document are retained in similar form in this update, there are three major changes. First, bronchiolocentric interstitial pneumonia (BIP) is recognised as a major interstitial pattern seen on lung biopsy with corresponding features on chest imaging. The 2013 document included bronchiolocentric patterns of interstitial pneumonia as a rare histological pattern that might be of value; however, such cases were excluded from the category of idiopathic interstitial pneumonia, as the published data were insufficient to justify formal recognition as an idiopathic entity at that time [2]. Expansion of this classification beyond idiopathic entities mandates integration of HP and other bronchiolocentric interstitial disorders. An additional consideration is that a substantial percentage of patients with bronchiolocentric patterns of disease on pathology and imaging have a non-HP diagnosis [7, 8]. To address this, "BIP " has been introduced as the overarching term to describe an airway-centred pathological and/or radiological pattern observable in HP and other interstitial pneumonias, such as CTD-ILD, aspiration, and drug-induced ILD. Incorporation of BIP as a pattern in this document better recognises the three main fibrosing patterns of interstitial pneumonia (usual interstitial pneumonia (UIP),

Downloaded from https://publications.ersnet.org on October 19, 2026 by guest. Please see licensing information on first page for reuse rights.

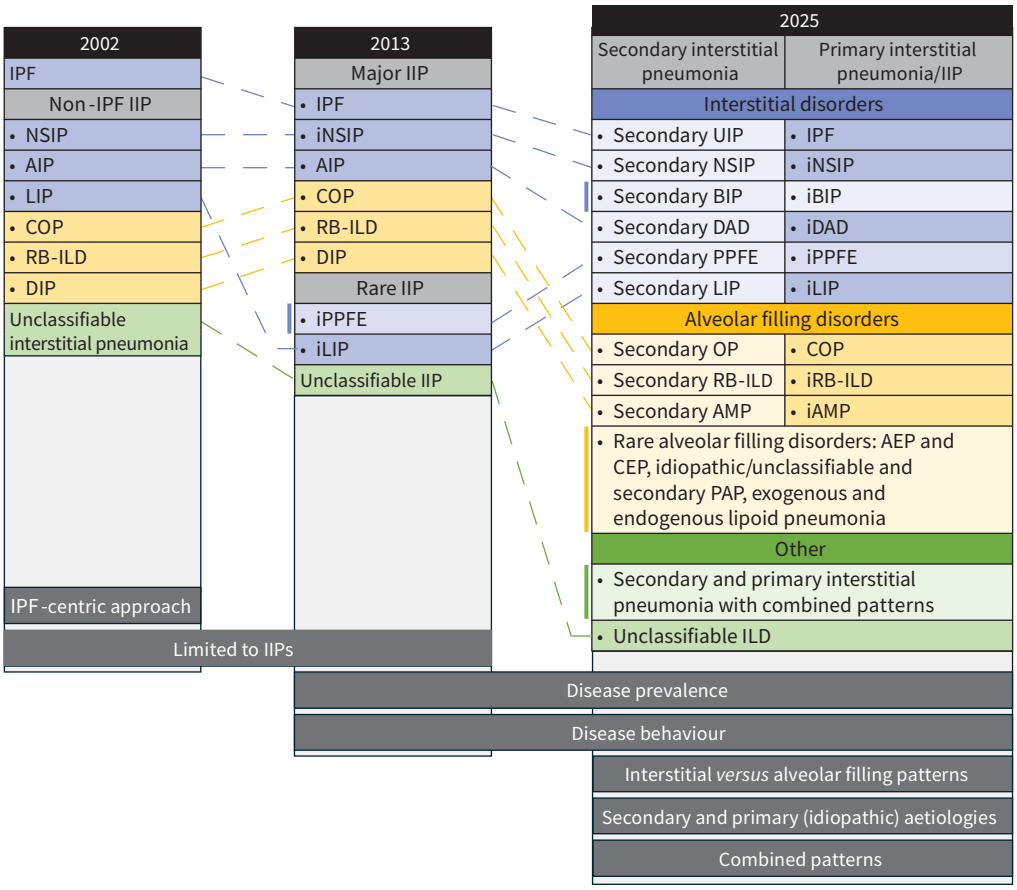

FIGURE 2 Major changes in interstitial pneumonia classification since the 2002 and 2013 approaches. The colour intensity of each cell indicates the timing that each pattern was introduced, with lighter shading for more recently introduced patterns. Grey boxes represent category headers. The first instance of a new addition to the 2002 classification is further indicated by a solid bar on the left of that new item. Individual patterns included in serial classifications are connected by a dashed line. Key distinguishing features considered in the 2002, 2013 and 2025 classifications are listed at the bottom of the figure in dark grey boxes. IPF: idiopathic pulmonary fibrosis; IIP: idiopathic interstitial pneumonia; NSIP: nonspecific interstitial pneumonia; AIP: acute interstitial pneumonia; LIP: lymphoid interstitial pneumonia; COP: cryptogenic organising pneumonia; RB: respiratory bronchiolitis; ILD: interstitial lung disease; DIP: desquamative interstitial pneumonia; PPFE: pleuroparenchymal fibroelastosis; UIP: usual interstitial pneumonia; BIP: bronchiolocentric interstitial pneumonia; DAD: diffuse alveolar damage; OP: organising pneumonia; AMP: alveolar macrophage pneumonia; AEP: acute eosinophilic pneumonia; CEP: chronic eosinophilic pneumonia; PAP: pulmonary alveolar proteinosis. The prefix "i" refers to idiopathic.

NSIP, and BIP), and is akin to UIP serving as the pattern seen in IPF and other diagnoses in which distinct terms are used to refer to pattern and multidisciplinary diagnosis. To provide further consistency with the other patterns of interstitial pneumonia, we propose that "HP" no longer be used to describe a pattern seen on chest imaging or lung biopsy, and that the term "HP" instead be reserved for the multidisciplinary diagnosis of HP. It is important to highlight that specific disease features seen on radiology (*e.g.* profuse centrilobular ground-glass nodules) and pathology (*e.g.* peribronchiolar granulomatous inflammation) in the setting of a BIP pattern can suggest a high confidence for HP even in the absence of a clear exposure. We recognise that this proposal is contentious and opinions within the committee differed on how to introduce the term "BIP" into clinical practice, but the committee anticipates that this proposal will serve as a template to support further studies in this area. Second, "idiopathic diffuse alveolar damage" (DAD) is introduced to replace acute interstitial pneumonia (AIP), which was considered an imprecise term given the potential for acute presentations of other interstitial pneumonias. Third, "alveolar macrophage pneumonia" (AMP) is introduced to replace the pathologically

Downloaded from https://publications.ersnet.org on October 19, 2026 by guest. Please see licensing information on first page for reuse rights.

TABLE 2 Typical pathological, radiological and clinical features of major interstitial pneumonia patterns

	Clinical features	Radiological features	Pathological features
Interstitial patterns			
UIP	Presentation: chronic onset with high likelihood of progression and potential for rapid worsening and acute exacerbation Risk factors: more frequent in older males with a smoking history, particularly for IPF	Subpleural and usually lower lung predominance. Fibrotic changes including reticulation, peripheral traction bronchiectasis, and honeycombing	Dense fibrosis, typically including fibroblast foci, with a predilection for subpleural and paraseptal parenchyma; architectural distortion in the form of honeycomb change juxtaposed with relatively unaffected lung parenchyma
NSIP	Presentation: chronic onset, but with variable risk of progression. Potential for rapid worsening, especially with concurrent organising pneumonia Risk factors: more common in younger females, often with a background of CTD	Lower-lobe predominance, commonly with subpleural sparing. Ground-glass opacities, fine reticulation, and traction bronchiectasis, without honeycombing	Cellular NSIP: cellular interstitial infiltrate of lymphocytes causing thickening of alveolar walls with no fibrosis or granulomas Fibrotic NSIP: diffuse thickening of alveolar walls by fibrosis with traction bronchiolectasis; no bronchiolocentricity, honeycombing, or granulomas
BIP	Presentation Non-fibrotic BIP: acute/subacute onset frequently with respiratory and systemic symptoms Fibrotic BIP: chronic onset but with variable risk of progression. Potential for rapid worsening, especially with ongoing exposure Risk factors No clear age or sex predilection. Positive exposure history for HP-associated antigens	Non-fibrotic BIP: centrilobular ground-glass nodules, mosaic attenuation, and/or lobular air trapping Fibrotic BIP: peribronchovascular ground-glass, traction bronchiectasis, mosaic attenuation, lobular air trapping, and three-density sign. Features can overlap with non-fibrotic BIP	Non-fibrotic BIP: bronchiolocentric chronic inflammation ± non-necrotising granulomatous inflammation Fibrotic BIP: bronchiolocentric fibrosis often with peribronchiolar metaplasia ± bronchiolocentric inflammation
DAD	Presentation: acute worsening with high likelihood of residual fibrosis and potential for ongoing progression Risk factors: vary with underlying aetiology (*e.g.* sepsis, aspiration, pneumonia, CTD-ILD)	Patchy or diffuse ground-glass opacity that may progress to fibrosis over time with significant traction bronchiectasis, architectural distortion and honeycombing	Exudative phase: alveolar septa are thickened by interstitial oedema, pneumocyte hyperplasia and surface hyaline membranes Organising phase: evolution into predominant interstitial involvement by loose organising connective tissue and exuberant proliferation of pneumocytes, often with some atypia Fibrotic phase: DAD can progress to interstitial fibrosis with varying features
PPFE	Presentation: chronic onset, but with variable risk of progression. Frequently associated with significant weight loss Risk factors: no clear age or sex predilection	Biapical pleural thickening, dense subpleural confluent fibrosis and traction bronchiectasis with volume loss and upward hilar retraction, which may extend more caudally to involving the major fissures, and occasionally into the middle and lower lobes. May include platythorax, deep sternal notch, and/or tracheal deviation. Often coexists with additional patterns, especially with UIP	Upper zone pleural fibrosis with subpleural intra-alveolar fibroelastosis, often with extension of fibrosis into underlying lung parenchyma. Some cases may lack upper lobe predominance. At least one-third of cases coexist with additional patterns or specific findings characteristic of UIP, NSIP, BIP, granulomas, or mycobacterial or fungal infection
LIP	Presentation: insidious onset with slow progression Risk factors: no clear age or sex predilection for idiopathic LIP. Risk factors for secondary LIP vary with underlying aetiology	Mid- to lower-lobe-predominant thin-walled lung cysts with reticulation, ground-glass opacity, bronchovascular thickening and perilymphatic interstitial thickening; randomly distributed or lower-lobe-predominant thin-walled cysts may be the only or dominant finding	Dense and diffuse interstitial infiltrate of lymphocytes and plasma cells expanding the alveolar septa, often with peribronchial and peribronchiolar lymphoid follicles, sometimes showing germinal centres. Lymphoplasmacytic infiltrate is polyclonal. Dutcher bodies are absent

Continued

https://doi.org/10.1183/13993003.00158-2025

Downloaded from https://publications.ersnet.org on October 19, 2026 by guest. Please see licensing information on first page for reuse rights.

TABLE 2 Continued

	Clinical features	Radiological features	Pathological features
Alveolar filling patterns			
Organising pneumonia	Presentation: acute or subacute onset of respiratory ± constitutional symptoms. Typically reversible, but potential for residual fibrosis; low potential for ongoing progression for COP, with higher potential for recurrence or progression for some causes, particularly CTD Risk factors: no clear age or sex predilection for COP. Risk factors for secondary organising pneumonia vary with underlying aetiology	Patchy consolidation with air bronchograms, patchy ground-glass opacities, focal nodules, and/or mass-like lesions, sometimes featuring a halo sign, reversed halo sign, perilobular pattern, or air-bronchograms	Intra-alveolar buds of loose connective tissue predominantly within alveoli, alveolar ducts ± respiratory bronchioles. Interstitial inflammation is typically mild in COP. Secondary organising pneumonia can be associated with ancillary findings
RB-ILD	Presentation: subacute onset with potential for improvement or resolution with smoking cessation Risk factors: adult smokers with slight male predominance	Upper-lobe-predominant centrilobular ground-glass nodularity	Accumulation of lightly pigmented macrophages in airspaces associated with a mild chronic inflammatory cell infiltrate. Lymphoid aggregates and fibrosis may also be present. Bronchiolocentric distribution
AMP	Presentation: highly variable onset, progression in a subset Risk factors: adult smokers with slight male predominance, although rare cases have been reported in nonsmokers	Middle- to lower-lung-predominant with variable upper lung involvement, although may be predominantly peripheral. Primarily patchy and confluent ground-glass opacities with smooth reticulation. Cystic spaces may be present within the ground-glass; emphysema, and traction bronchiectasis may also be seen	Accumulation of lightly pigmented macrophages in airspaces associated with a mild chronic inflammatory cell infiltrate. Lymphoid aggregates and fibrosis may also be present. Diffuse distribution
Rare AFPs (supplementary table S2)			

UIP: usual interstitial pneumonia; NSIP: nonspecific interstitial pneumonia; BIP: bronchiolocentric interstitial pneumonia; DAD: diffuse alveolar damage; PPFE: pleuroparenchymal fibroelastosis; LIP: lymphoid interstitial pneumonia; RB-ILD: respiratory bronchiolitis-interstitial lung disease; AMP: alveolar macrophage pneumonia; AFPs alveolar filling pattern; IPF: idiopathic pulmonary fibrosis; CTD: connective tissue disease; HP: hypersensitivity pneumonitis; COP: cryptogenic organising pneumonia.

https://doi.org/10.1183/13993003.00158-2025

Downloaded from https://publications.ersnet.org on October 19, 2026 by guest. Please see licensing information on first page for reuse rights.

inaccurate term of desquamative interstitial pneumonia (DIP), which is not the result of alveolar pneumocyte desquamation as originally thought. These changes in terminology aim to reduce confusion and better reflect the underlying pathology of these diseases.

Subclassification as interstitial (fibrotic versus *non-fibrotic) and alveolar filling disorders*

The 2013 document subcategorised idiopathic interstitial pneumonias as chronic fibrosing, smoking-related, and acute/subacute subtypes. The current document advances this in two key areas while still highlighting the importance of disease behaviour. First is the separation of patterns into interstitial and alveolar filling disorders based on the predominant location of the lung injury as seen histologically and radiologically, recognising that pure interstitial or pure alveolar disorders are uncommon and that all compartments of the lung are frequently affected. Interstitial disorders are further subgrouped into fibrotic and non-fibrotic presentations, which is crucial for patients with NSIP or BIP patterns that can present across this spectrum. Alveolar filling disorders are further subgrouped by the type of cells or fluid occupying the alveoli. This updated classification is rooted in distinguishable characteristics that have biological, prognostic, and therapeutic implications. Second, the importance of anticipated disease behaviour is maintained and further clarified, recognising that there remains substantial variability across and within major categories and individual patterns. Recent clinical trials have shown the benefit of antifibrotic medications nintedanib and pirfenidone in patients with PPF regardless of the underlying diagnosis [9–11], supporting the disease behaviour concept and suggesting specific criteria for objectively defining disease progression [12–14]. A recent clinical practice guideline has provided further guidance on this concept and a definition for PPF [3].

Consideration of diagnostic confidence

There is often uncertainty in the diagnosis of interstitial pneumonia given the absence of a pathognomonic test for most diagnoses. A previous working group addressed this issue, labelling patients with diagnostic confidence ⩾90% as a confident diagnosis, 51–89% as a provisional diagnosis (indicating a substantial likelihood that further evaluation may be informative), and the absence of a leading diagnosis with >50% confidence representing unclassifiable ILD (supplementary figure S1) [15]. This approach has potential clinical utility, with a previous study suggesting that clinicians often use a threshold of 70% confidence in a diagnosis of IPF as sufficient certainty to support management decisions without pursuing further invasive testing [16]. The committee members have further adopted this approach histologically and radiologically, both in terms of assignment of confidence in an individual imaging or biopsy pattern as well as how likely a given pattern is to represent a specific multidisciplinary diagnosis. For example, a patient with a pattern of BIP on biopsy or computed tomography (CT) may have specific morphological features that suggest a high confidence of HP, which is important to convey in corresponding reports. This approach more appropriately acknowledges diagnostic uncertainty and calls attention to the need for careful reassessment of diagnoses over time.

Diagnostic approach

There is no pathognomonic test for most interstitial pneumonias, with diagnosis established through integration of multiple domains. The diagnostic approach typically starts with identification of a suggested radiological pattern on chest CT. This begins first with separation into interstitial and alveolar filling disorders, with further division into individual patterns (table 2 and supplementary table S2). Radiological features are then integrated with clinical and laboratory data (*e.g.* autoimmune serology), which may be sufficient to provide a confident diagnosis and/or specific management guidance. Additional molecular studies are not sufficiently validated to support routine use with high sensitivity or specificity, but are helpful in some situations. In patients with substantial diagnostic and therapeutic uncertainty, the committee members often proceed with more invasive tests such as lung biopsy, with this decision requiring a detailed discussion of the benefits and risks with the patient.

The lack of a pathognomonic test for most interstitial pneumonias highlights the importance of carefully considering and documenting diagnostic confidence throughout the evaluation process, including the confidence in the leading diagnosis and the list of potential differential diagnoses [15]. Using standardised language in reporting radiological and pathological patterns facilitates discussion and improves the ability to arrive at a final diagnosis (supplementary table S3). For example, the committee suggests that a radiological or pathological pattern of BIP be reported as “BIP pattern, favour HP but with differential diagnosis including CTD-ILD and drug-associated ILD”, or “BIP pattern, favour HP”, depending on the extent to which ancillary features suggest different clinical diagnoses. Such information would then be integrated with clinical data to support a multidisciplinary diagnosis with confidence that should similarly be documented in a standardised and explicit manner [15].

Downloaded from https://publications.ersnet.org on October 19, 2026 by guest. Please see licensing information on first page for reuse rights.

Major histopathological and radiological patterns

Interstitial patterns

The most common patterns of interstitial pneumonias are UIP, NSIP and BIP. These patterns are frequently associated with PPF and a poor prognosis, although NSIP and BIP can also present with limited fibrosis and greater cellularity that portend a better expected prognosis. Although PPFE and DAD are not always predominantly interstitial in certain phases of disease progression, the committee believed it most appropriate to place these in the interstitial category as described herein for each pattern. Each interstitial pattern is frequently associated with secondary aetiologies; however, a substantial percentage of cases occur without a clear identifiable cause. For all patients, it is important to carefully consider and document the diagnostic confidence based on integration of clinical, radiological and laboratory investigations, and whether additional more invasive tests are appropriate [15]. There remains a need to obtain histopathology to assess the underlying interstitial pneumonia pattern in some patients without a high-confidence clinical-radiological diagnosis.

Usual interstitial pneumonia

UIP was originally defined histologically as a specific pattern on surgical lung biopsy [17, 18]. As described in recent clinical practice guidelines for the diagnosis of IPF [19], the hallmark pathological features include subpleural and paraseptal predominant interstitial fibrosis with temporal and spatial heterogeneity, abrupt transition of normal to fibrotic lung, subepithelial fibroblastic foci, and honeycombing (figure 3a–d) [20–23]. Up to 25% of surgical lung biopsies from patients with UIP/IPF have areas of NSIP, which reflect the spatial heterogeneity of the disease [24]. Predominant bronchiolocentricity, significant inflammation without background fibrosis, and granulomas are not seen in UIP. Features of acute lung injury, such as DAD and organising pneumonia, may be superimposed in acute exacerbation of UIP.

UIP is radiologically defined as subpleural and basal predominant fibrosis with honeycombing, without significant features suggesting an alternative diagnosis such as cysts, marked mosaic attenuation, predominant ground-glass, nodules, or consolidation (figure 3e–g) [19]. Probable UIP has the same features, but without honeycombing (figure 3h–j). Imaging patterns of UIP and probable UIP correlate strongly with histopathological features of UIP, allowing a confident diagnosis of IPF without lung biopsy in the appropriate clinical setting (*e.g.* males aged >60 years, who frequently have a smoking history) [3, 19], with a previous study suggesting that 70 % confidence in a clinical-radiological diagnosis of IPF may be considered sufficient to support management decisions without confirmation by lung biopsy [16]. A diagnosis of IPF can be made in patients with indeterminate or atypical clinical and/or radiological findings, but this typically requires a lung biopsy.

UIP is the pathological hallmark pattern of IPF, but can also be seen in secondary causes such as CTD-ILD, fibrotic HP, and asbestosis [25–28], particularly in more advanced disease [29]. These non-IPF diagnoses are sometimes suspected based on imaging or pathology appearance, but can sometimes be difficult to distinguish from IPF [23, 25, 28, 30]. CTD-UIP is often associated with sharply demarcated lower lobe honeycombing and/or exuberant honeycombing on imaging and prominent chronic inflammation with lymphoid aggregates containing germinal centres on pathology. Associated patulous oesophagus, mixed pattern of lung injury including organising pneumonia and pleuritis or pleural effusion is also suggestive of CTD-UIP. HP-UIP is often suggested by subtle findings of airway-centred abnormalities, including the presence of peribronchiolar granulomatous inflammation, or extension of disease beyond peripheral and basal regions (box 1).

Nonspecific interstitial pneumonia

NSIP encompasses a spectrum of non-fibrotic (*i.e.* cellular) and fibrotic patterns. NSIP most often presents with underlying causes such as CTD or drug toxicity, is sometimes seen in fibrotic HP, AMP (formerly referred to as DIP), or following cryptogenic or secondary organising pneumonia, and is rarely idiopathic [8, 31]. Based on a recent systematic review of 122 publications that included 8266 patients, fibrotic NSIP is the most common ILD pattern in CTD-ILD (range 27–76% of all CTD-ILD), excluding rheumatoid arthritis associated ILD where UIP is slightly more common at 46% of all cases [31, 32]. A study of 109 patients who had lung biopsy of multiple lobes showed that a histological pattern of NSIP can also coexist with UIP, in which case the histological pattern is considered to be UIP [24]. Autoimmune serologies for CTD-ILD are the only laboratory tests typically used to screen for an underlying cause of an NSIP pattern, while serum precipitins for HP rarely have clinical utility in this setting [25, 33, 34].

Histologically, NSIP is characterised by homogeneous, uniform thickening of alveolar walls by varying amounts of interstitial inflammation and/or fibrosis (figure 4a–c) [24, 35–41]. The majority of biopsied NSIP cases are primarily fibrosing (with or without some cellularity) [35]. Honeycombing, organising

Downloaded from https://publications.ersnet.org on October 19, 2026 by guest. Please see licensing information on first page for reuse rights.

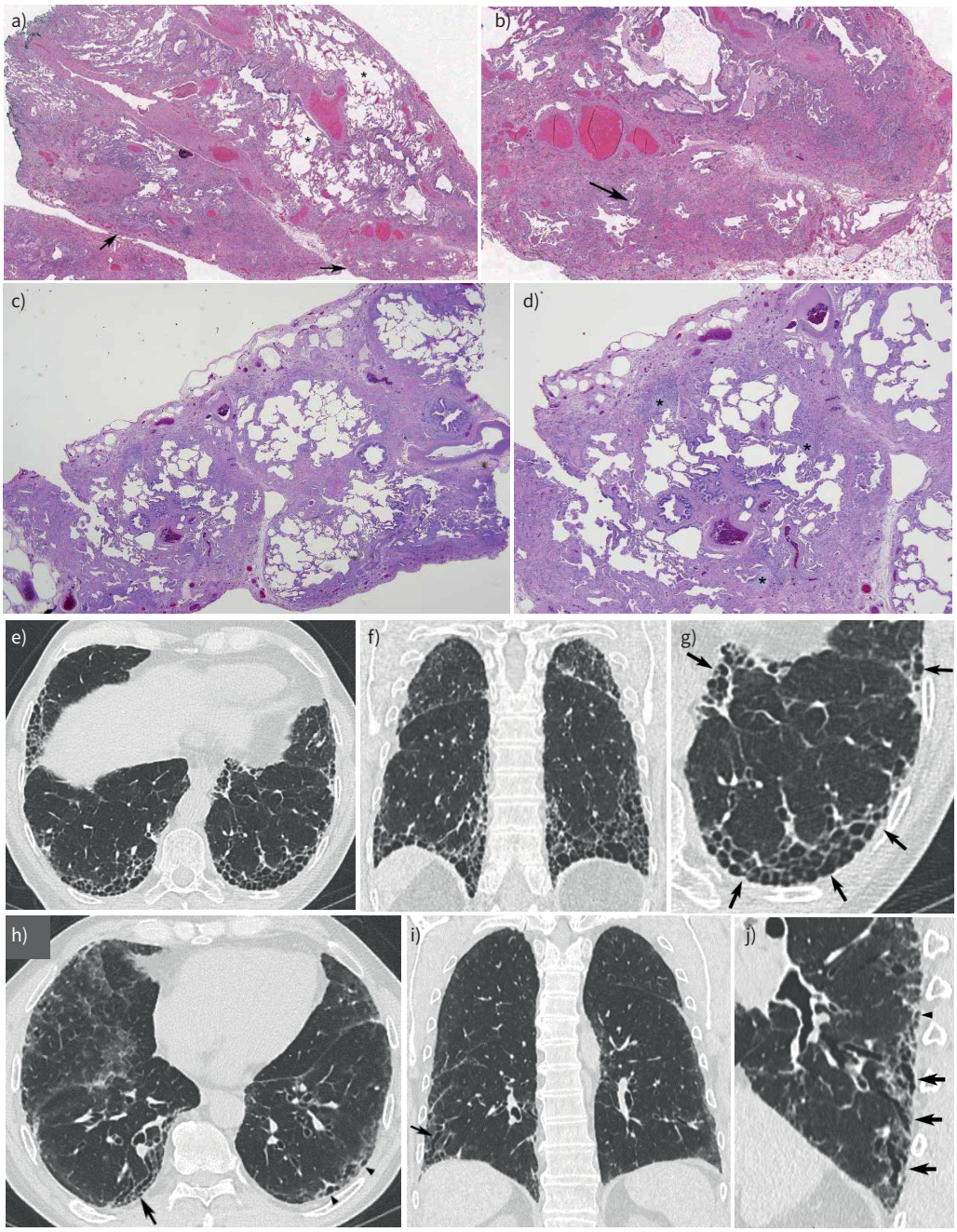

FIGURE 3 Pathological (haematoxylin and eosin stain) and radiological features of the usual interstitial pneumonia (UIP) and –probable UIP pattern. a) Low power of magnification photomicrograph of typical UIP shows dense fibrosis with a predilection for subpleural and paraseptal parenchyma with associated architectural distortion in the form of microscopic honeycomb change (arrows) juxtaposed with relatively unaffected lung parenchyma (*). Visceral pleura is seen in the upper portion of the figure. b) Higher magnification photomicrograph of typical UIP shows subpleural scarring and honeycomb change with associated fibroblast foci (arrow). c) Low magnification photomicrograph of probable UIP shows subpleural and paraseptal predominant patchwork fibrosis that is less well developed and lacks the degree of associated architectural distortion in the form of either destructive scarring or honeycomb change usually seen in typical UIP. d) Higher magnification photomicrograph of probable UIP showing patchy fibrosis and fibroblast foci (*), but without the extent of scarring and honeycomb change usually seen in typical UIP. e) Axial chest computed tomography (CT) and f) coronal reconstruction shows honeycombing with subpleural and basal predominance with some mild ground-glass opacity. g) Magnified view of the left lower lobe showing typical characteristics of honeycombing, consisting of clustered cystic airspaces with well-defined walls and variable diameters, seen in

Downloaded from https://publications.ersnet.org on October 19, 2026 by guest. Please see licensing information on first page for reuse rights.

single or multiple layers (arrows). h) Axial chest CT and i) coronal reconstruction of both lungs and j) magnified sagittal view of the right lower lobe showing a reticular pattern with peripheral bronchiolectasis with subpleural and basal predominance. Depending on their orientation relative to the plane of the CT section, peripheral traction bronchiolectasis appear as tubular (arrows) or cystic (arrowheads) structures. Note the concurrent presence of mild ground-glass attenuation in the subpleural areas of both lungs and the absence of honeycombing. UIP was proven at histology. Reproduced from [19] with permission.

BOX 1 Research priorities for UIP

- Are there biologically relevant subgroups of IPF that have therapeutic implications?
- Are there sufficient data to split some genetic disorders from IPF (*e.g.* telomeropathies)?
- Is application of novel molecular assays to BAL useful in patients with a radiologic pattern of UIP or probable UIP?
- What is the radiological-pathological correlation of a probable UIP pattern?

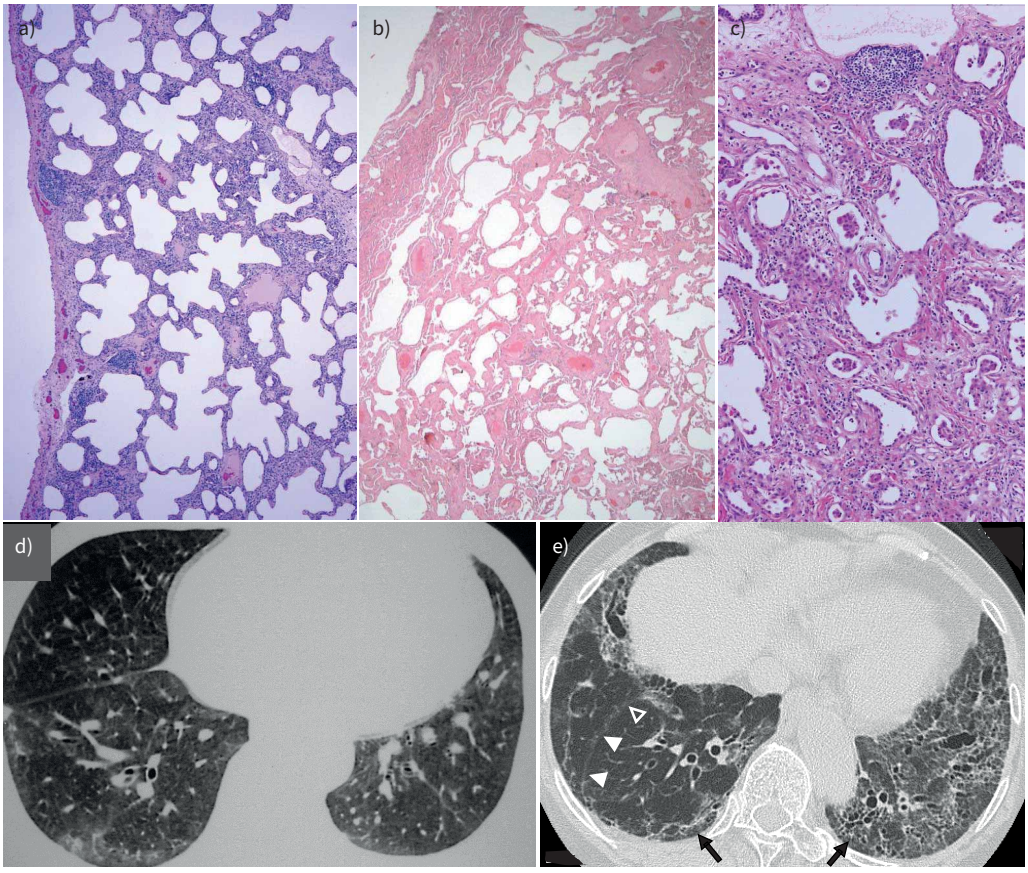

FIGURE 4 Pathological (haematoxylin and eosin stain) and radiological features of the nonspecific interstitial pneumonia (NSIP) pattern. a) Histological pattern of nonfibrotic NSIP shows a moderate cellular interstitial infiltrate of lymphocytes causing mild thickening of alveolar walls. The architecture of the lung is preserved and no bronchiolocentricity or granulomas are seen. b) Lung biopsy of fibrotic NSIP shows diffuse thickening of alveolar walls by fibrosis with no architectural remodelling, bronchiolocentricity, or honeycombing. c) Higher power of fibrotic NSIP shows diffuse thickening of alveolar walls by uniform fibrosis without fibroblastic foci. d) Axial computed tomography (CT) of non-fibrotic NSIP shows lower lung predominant ground-glass and minimal reticulation without traction bronchiectasis or other signs of fibrosis, and with subpleural sparing. e) Axial CT of fibrotic NSIP shows lower-lung-predominant reticular abnormality with traction bronchiectasis. Subpleural sparing is present (arrows). There is bilateral lower lobe volume loss with posterior displacement of the right major fissure (arrowheads).

Downloaded from https://publications.ersnet.org on October 19, 2026 by guest. Please see licensing information on first page for reuse rights.

pneumonia, bronchiolocentricity, granulomas, and fibroblastic foci are usually absent in the setting of pure NSIP [35, 42]. CT typically shows lower-lung-predominant ground-glass and reticular abnormality with traction bronchiectasis; the features may vary according to the proportion of cellularity and fibrosis (figure 4d and e) [36, 38, 39, 41, 43–53]. Approximately half of fibrotic NSIP cases have relative sparing of the subpleural lung (41% in a 2020 systematic review that included three studies, but 64% in a well-conducted study of 50 cases), a highly suggestive finding that helps distinguish NSIP from UIP [35, 51, 54]. As fibrosis progresses, lobar volume loss increases, traction bronchiectasis and bronchiolectasis extend to more proximal airways, and reticular abnormality may increase [38, 55]. The presence of either histological or radiological organising pneumonia in combination with NSIP indicates a high likelihood of an underlying CTD or drug toxicity [56]. CTD is also suggested by presence of a patulous oesophagus, pleural thickening, pleural effusion, prominent lymphoid follicles, or a plasma cell rich lymphoid interstitial infiltrate. Disease behaviour of diagnoses associated with an NSIP pattern is heterogeneous. Cellular NSIP can regress substantially with immunomodulatory medication, whereas fibrotic NSIP may progress despite such management.

Lung biopsy is not indicated in typical cases of fibrotic NSIP that are linked to an underlying cause such as a CTD or high-risk medication exposure temporally associated with disease onset, given the high confidence in the diagnosis of CTD-ILD in this setting. However, NSIP can be radiologically indistinguishable from UIP [43, 52, 57], BIP (including fibrotic HP) [25, 33], or AMP, and thus may warrant lung biopsy for histological interstitial pneumonia pattern diagnosis in patients without an identified underlying cause [58]. The previous recommendation that adequate histopathology and review by multidiscipliniary discussion is needed to establish a confident diagnosis of idiopathic NSIP was informed by its rarity, lack of clearly distinguishing clinical, radiological, and laboratory features, and apparent better survival and different treatment approaches compared to IPF [2, 35]; however, additional data are needed to confirm the appropriateness of this approach. The wide range in prevalence of idiopathic NSIP in various cohorts probably relates in large part to whether histopathology was required to support this diagnosis, with more stringent diagnostic criteria resulting in a larger proportion of patients being considered to have unclassifiable ILD (box 2).

Bronchiolocentric interstitial pneumonia

Many patients with interstitial pneumonia have a pattern of airway-centred disease. This includes histological and radiological patterns suggestive of non-fibrotic and fibrotic HP as described in recent HP guidelines [25, 33], as well as other bronchiolocentric patterns that have been referred to using a variety of terms, including airway-centric/centred disease or fibrosis, airway-centred interstitial pneumonia, airway-centred interstitial fibrosis, bronchiolocentric pattern of interstitial pneumonia, and bronchiolocentric pattern of interstitial fibrosis [59–65]. The term BIP was originally proposed as a type of interstitial pneumonia in 1969 [66], and we again propose re-introduction of the term BIP, albeit with a different definition. BIP is recommended as an overarching term to define the histological and/or radiological pattern of predominantly airway-centred interstitial pneumonia, which can be seen in the aetiological setting of HP as well as CTD-ILD, aspiration, and inhalational or medication exposures. A pattern of BIP is thus similar to other common interstitial patterns, such as UIP and NSIP, in that all major patterns can occur in a variety of clinical diagnoses.

BIP is not a new pattern and is instead proposed primarily as a change in language that allows use of distinct and independent terms for patterns and clinical aetiology, consistent with the approach taken for other patterns of interstitial pneumonia. We therefore propose that the term “HP” be used only to describe the multidisciplinary diagnosis of HP, which can present with a variety of radiological/histological patterns, including BIP, NSIP, and UIP. Although this is a change from terminology used in recent HP guidelines [25, 33], many patients with these airway-centred patterns cannot be confirmed to have HP after

BOX 2 Research priorities for NSIP

- Is idiopathic NSIP a distinct multidisciplinary diagnosis?
- Can idiopathic NSIP present with an acute or subacute onset and clinical course?
- What is the distinction between NSIP and probable/indeterminate for UIP and indeterminate for HP?
- Does BAL distinguish NSIP from UIP?
- What is the radiological-pathological correlation of NSIP?
- Is surgical lung biopsy or TBLC necessary to establish a confident multidisciplinary diagnosis of idiopathic NSIP?

Downloaded from https://publications.ersnet.org on October 19, 2026 by guest. Please see licensing information on first page for reuse rights.

multidisciplinary review (36% in a recent subgroup analysis of 164 patients with a radiological pattern of "typical HP" had a diagnosis other than HP and another 34% had no clear cause identified), with alternatives including, but not restricted to, CTD-ILD (particularly rheumatoid arthritis-associated ILD), aspiration, and other inhalational or medication exposures [8, 25, 33]. Labelling these patients with a pattern of HP on histology or radiology suggests a multidisciplinary diagnosis that may not be accurate, so the introduction of a category of BIP will hopefully allow better categorisation of cases that are not HP and support further studies related to the provisional clinical entity of idiopathic BIP. This new terminology has potential to be confusing given the change from recent HP guidelines [25, 33]; however, updating terminology will encourage more precise classification of HP, support greater recognition of non-HP disorders that can have overlapping clinical features, imaging, and pathology, and provide a framework for future research to define the features of BIP in patients with diagnoses other than HP [54, 67–74]. The summaries for clinical, CT, and pathology features of BIP provided herein are primarily drawn from existing HP literature, including the previous guidelines on the diagnosis of HP [25, 33], as well as other causes of airway-centred interstitial pneumonia that have been referred to using a variety of terms. Importantly, although some cases previously labelled as HP will now be classified as idiopathic BIP, the proposed change in terminology does not alter the diagnostic approaches taken in recent HP guidelines.

BIP can have a mixture of both inflammatory and fibrotic interstitial pathology (figure 5a–d) [67]. The histological features of non-fibrotic (or cellular) BIP include chronic lymphocyte-predominant inflammation surrounding bronchioles that may also include non-necrotising granulomatous inflammation [25, 33, 59, 73, 75]. Fibrotic BIP is characterised by bronchiolocentric fibrosis (± chronic inflammation), often with peribronchiolar metaplasia in adjacent airspaces consisting of ciliated, pseudostratified respiratory epithelium, or rarely squamous metaplasia in cases with prominent distal airway injury [7, 25, 33, 60–65, 67–69, 75–84]. Architectural remodelling with airway narrowing and/or bronchiolectasis with mucostasis are common sequelae of fibrotic BIP. Non-fibrotic and fibrotic BIP often have associated interstitial involvement of adjacent alveolar walls by inflammation or fibrosis, respectively. The presence of patchy and small foci of granulomatous inflammation in a peribronchiolar distribution is highly suggestive of HP as a secondary cause of BIP. Foci of organising pneumonia and/or foamy macrophage accumulation within alveolar airspaces probably reflect proximal airway injury (*e.g.* through aspiration). Aspiration is also suggested by multinucleated giant cells and suppurative granulomas. Although these features are not specific, the presence of foreign material can be confirmatory [85].

The classical CT features of non-fibrotic BIP include profuse poorly defined centrilobular nodules reflecting peribronchiolar inflammation and ground-glass opacities with mosaic attenuation (three-density sign) that represents a component of small airway obstruction (figure 5e). These features are highly suggestive of HP in the correct clinical context, although may be seen in other diagnoses, particularly in milder cases when centrilobular nodules are less profuse or when patchy ground-glass abnormality is present without mosaic attenuation. CT features of fibrotic BIP are less well-characterised, but include ground-glass opacities, reticulation, traction bronchiectasis, mosaic attenuation, three-density sign, and expiratory air trapping, often in a peribronchovascular distribution (figure 5f). These features are similarly highly suggestive of HP in the appropriate clinical context but can also be seen in other diagnoses, with one study of 645 patients showing that 9% of patients with CTD-ILD had an imaging pattern consistent with BIP [8, 86]. The radiological features in cases of histologically confirmed non-fibrotic and fibrotic BIP requires further investigation.

In some cases, there are histological and/or radiological features in a BIP pattern that confer a high confidence for a specific multidisciplinary diagnosis (*e.g.* peribronchiolar granulomatous inflammation is highly suggestive of HP). The committee suggests that presence of these features and the diagnostic confidence they portend should be communicated in the pathology or radiology report (*e.g.* "BIP pattern, strongly favour HP"), as this information is critical to the overall multidisciplinary diagnosis [15]. In patients with a BIP pattern of unclear aetiology, we propose that "idiopathic BIP" be used as a provisional (or "working") diagnosis to both call attention to the need for careful consideration of all potential causes, including during follow-up, and to acknowledge that additional studies are needed to better characterise this entity. Key advantages of introducing BIP are to harmonise the classification and terminology across major interstitial pneumonia subtypes and to facilitate future research to identify and better define potentially unique patient populations or disease subtypes. Differentiating between final diagnoses of HP and a working diagnosis of idiopathic BIP requires careful evaluation for a potential exposure, as described in recent guidelines and a workshop report [33, 34, 58], and it may still be possible to make a confident diagnosis of HP in some cases with classic histological and/or radiological findings even in the absence of an identified antigen. It is critically important to pursue identification of occult exposures in such situations, including a comprehensive occupational and environmental exposure history and sometimes

Downloaded from https://publications.ersnet.org on October 19, 2026 by guest. Please see licensing information on first page for reuse rights.

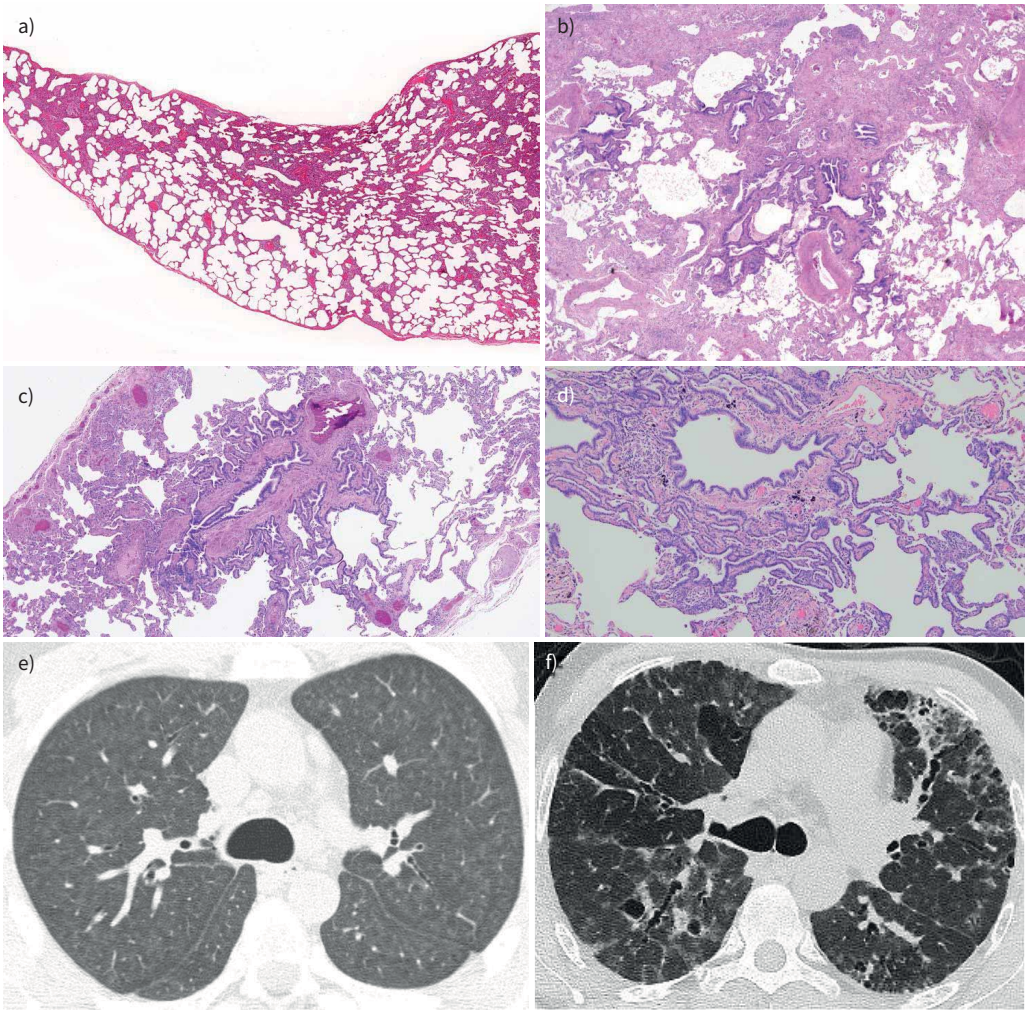

FIGURE 5 Pathological (haematoxylin and eosin stain) and radiological features of the bronchiolocentric interstitial pneumonia (BIP) pattern. a) Histological pattern of non-fibrotic BIP with granulomatous and lymphoplasmacytic inflammation within bronchiolar walls, with extension of inflammation into adjacent alveolar walls, probably representing BIP secondary to hypersensitivity pneumonitis (HP). b) Histological pattern of fibrotic BIP characterised by bronchiolocentric fibrosis, with associated peribronchiolar metaplasia and architectural remodeling with airway narrowing, mucostasis and associated interstitial fibrosis of adjacent alveolar walls. c) Lung biopsy of fibrotic BIP with prominent peribronchiolar metaplasia. d) Lung biopsy of mixed non-fibrotic and fibrotic BIP with scattered foci of granulomatous inflammation as well as bronchiolocentric fibrosis, peribronchiolar metaplasia and associated interstitial fibrosis of adjacent alveolar walls. e) Axial computed tomography (CT) of non-fibrotic BIP diffuse ground-glass centrilobular nodularity without traction bronchiectasis or other signs of fibrosis. f) Axial CT of fibrotic BIP shows diffuse axial and craniocaudal distribution of the three-density sign, consisting of multiple regions of lung with increased, normal, and decreased density, along with reticulation and traction bronchiectasis. This combination of findings would be referred to as a “typical HP” pattern in recent clinical practice guidelines on HP and is instead referred to in this document as a “fibrotic BIP” pattern. Scattered cysts are also present, mainly in the right lower lobe.

involving a workplace and/or multidisciplinary evaluation with industrial hygiene or occupational respiratory medicine expertise [34]. HP questionnaires are often geographically specific, but may identify otherwise occult exposures [87, 88]. Similar to other patterns of interstitial pneumonia, it is only after an extensive search for a potential aetiology that the committee considers a diagnosis of idiopathic BIP, most notably including exposures that would suggest a diagnosis of HP. When this search is unrevealing, a lung biopsy is sometimes appropriate to confirm the histologic pattern given the relatively limited data that currently exist on radiology-pathology correlation.

Downloaded from https://publications.ersnet.org on October 19, 2026 by guest. Please see licensing information on first page for reuse rights.

BOX 3 Research priorities for BIP

- What is the pathogenesis of BIP?
- What are the potential aetiologies of BIP?
- Is idiopathic BIP a distinct diagnosis?
- What minimum tests are required to exclude a diagnosis of HP in patients with a BIP pattern?
- Can idiopathic BIP present with an acute or subacute onset and clinical course?
- What is the natural history of idiopathic and secondary causes of BIP?
- Is there a clinical or molecular distinction between BIP and previous descriptions of fibrotic HP patterns?
- Does BAL distinguish fibrotic BIP from UIP?
- Does idiopathic BIP present with distinct CT and/or biopsy features compared to secondary aetiologies?
- What is the radiological-pathological correlation of BIP?
- Is lung biopsy necessary to establish a confident multidisciplinary diagnosis of idiopathic BIP?

Although >80% of the committee was in favour of including BIP as a major interstitial pneumonia pattern and introducing idiopathic BIP as a provisional multidisciplinary diagnosis, there were three main concerns highlighted in the discussions on this topic that led to four members of the committee requesting to not be included as co-authors. First, that introducing BIP as a major interstitial pneumonia pattern would create confusion in the context of relatively recent HP guidelines that describe the above features as defining a "typical HP pattern". However, after extensive deliberations, most of the committee believed it appropriate to use separate terms for morphological pattern and multidisciplinary diagnosis [25, 33]. Second, as described earlier, some patients have highly specific biopsy findings that suggest a high confidence in a multidisciplinary diagnosis of HP despite the inability to identify an aetiological exposure. The committee therefore decided that "idiopathic BIP" should remain a provisional clinical entity and should not be used if information from multidisciplinary review provides a confident diagnosis of HP or another aetiology. The committee further emphasises the importance of maintaining high vigilance for potential aetiological exposures in this situation. Third, it was considered whether there was a need for more evidence and/or greater uptake of this term in the literature prior to it being suggested in this document and adopted in clinical practice. However, most of the committee believed there was sufficient evidence and conceptual rationale to support introduction of BIP as a pattern to be used in pathology and imaging, but with idiopathic BIP being introduced only as a provisional multidisciplinary diagnosis until further evidence is published. Most notably, the committee highlights the need for a workshop to further study BIP, similar to the 2008 report on NSIP [35], additional study into geographic differences that might impact the approach to idiopathic BIP (*e.g.* in regions with high prevalence of HP such as India) [89], and additional studies on the natural history and response to different treatment options for different causes of the fibrotic BIP pattern (box 3).

Diffuse alveolar damage

DAD is a pattern of lung injury histologically characterised by acute and organising phases, with initial phases primarily affecting the entire alveolar septum and later phases also progressing to alveolar filling (figure 6a and b) [2, 90–96]. Alveolar septa are thickened by early interstitial oedema, pneumocyte hyperplasia, and surface hyaline membranes, sometimes followed by a pattern of organising pneumonia and collapse of interstitial structures. However, in the organising phase of DAD, the loose connective tissue is usually mostly situated within the alveolar walls rather than within intraluminal distal airspaces as seen in organising pneumonia. CT findings include ground-glass (often bilateral and patchy with focal sparing), consolidation (most often dependent), and traction bronchiectasis or bronchiolectasis (figure 6c and d) [91–93, 96–102]. Extensive pulmonary abnormalities and bronchial dilatation early in the course of disease are predictive of mortality [102, 103].

DAD presents with acute or subacute respiratory distress, often requires hospitalisation, and has a high mortality [92, 93, 97]. It is sometimes reversible, but can evolve to irreversible fibrosis, which was reported to occur in 61% of 23 patients who had an initial illness of duration >3 weeks and 24% of 54 patients who had 1–3 weeks of acute illness in a previous autopsy study [94]. It is the cardinal histological pattern in acute respiratory distress syndrome and is caused by a variety of infections, drugs, inhalational injuries, CTDs (especially inflammatory myopathy), and other lung insults. Most cases of acute exacerbation of interstitial pneumonia are characterised by a DAD pattern [104]. Idiopathic DAD was previously referred to as acute interstitial pneumonia (AIP) [2]; however, AIP is an imprecise term since other interstitial pneumonias can present acutely. Biopsies are typically not performed given the high mortality associated with surgical lung biopsy in patients with acute respiratory illness (up to 16% in patients admitted to

Downloaded from https://publications.ersnet.org on October 19, 2026 by guest. Please see licensing information on first page for reuse rights.

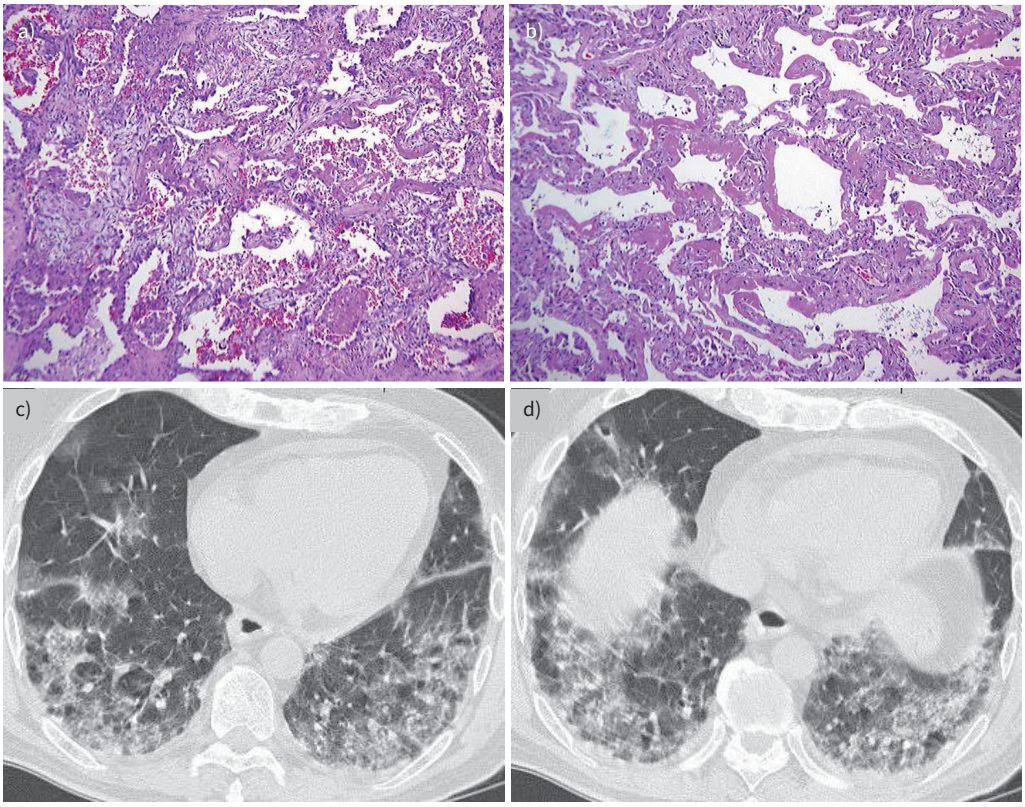

FIGURE 6 Pathological (haematoxylin and eosin stain) and radiological features of the diffuse alveolar damage (DAD) pattern. a) Lung biopsy of organising DAD shows alveolar walls diffusely thickened by loose organising connective tissue with less conspicuous hyaline membranes than seen in exudative (acute) DAD. b) Lung biopsy of exudative DAD shows alveolar walls diffusely thickened by prominent hyaline membranes and oedema with mild organising connective tissue. c and d) Axial chest computed tomography of DAD shows bilateral confluent areas of ground-glass attenuation. Subtle distortion is visible in the subpleural regions, mainly in the left lower lobe.

hospital for respiratory reasons in one claims-based study) [105], although bronchoalveolar lavage (BAL) and other less-invasive sampling techniques may aid in the management of patients by assessing for active infection or identifying underlying diseases such as a cancer (box 4) [106, 107].

Pleuroparenchymal fibroelastosis

PPFE was included as a rare entity in the 2013 document, but has since been increasingly recognised either in isolation or associated with other interstitial pneumonias [2]. PPFE can be idiopathic or associated with secondary causes [108–124], in which case there are more likely coexisting patterns such as UIP, NSIP, or BIP.

PPFE is histologically characterised by subpleural intra-alveolar fibroelastosis that frequently coexists with pleural fibrosis, consisting of marked subpleural thickening associated with abundance of elastic fibres (figure 7a and b) [108, 109, 116, 119–123, 125–129]. It typically infiltrates deep within the underlying

BOX 4 Research priorities for DAD

- Does the biology of DAD vary across different aetiologies?
- What are diagnostic criteria for DAD?
- What variables predict progression of DAD after the initial illness?
- What are the long-term outcomes of DAD?

Downloaded from https://publications.ersnet.org on October 19, 2026 by guest. Please see licensing information on first page for reuse rights.

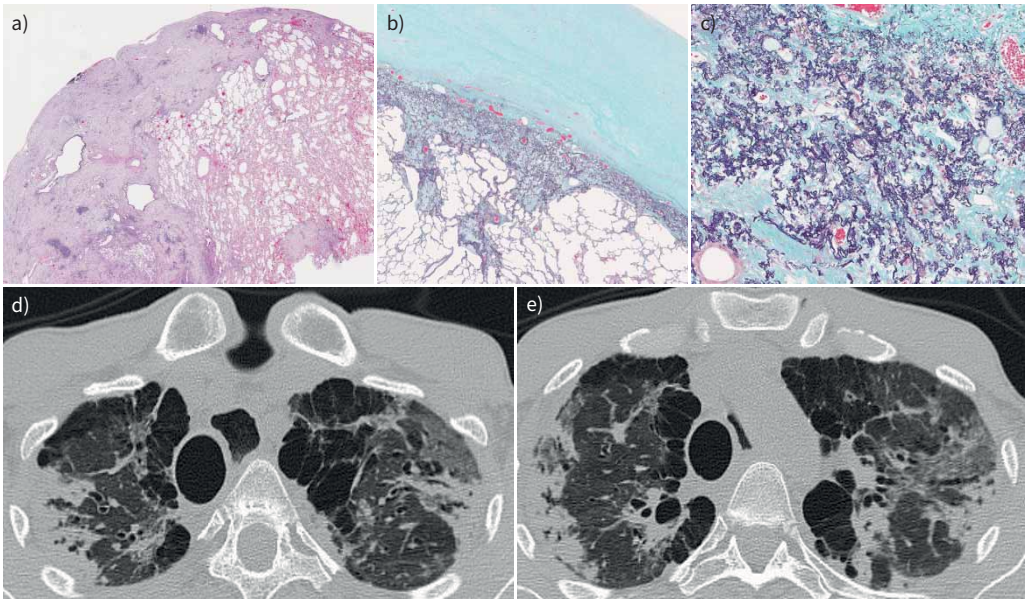

FIGURE 7 Pathological and radiological features of the pleuroparenchymal fibroelastosis (PPFE) pattern. a and b) Low-power view of the histological pattern of PPFE shows pleural fibrosis and subpleural intra-alveolar fibroelastosis (IAFE) extending into the deeper perilobular parenchyma; a) haematoxylin and eosin stain, b) Elastica–Masson stain. c) Higher-power view shows IAFE that is characterised by intra-alveolar collagenous fibrosis and alveolar septal elastosis. Elastosis is usually more prominent than collagenous fibrosis, without architectural distortion; Elastica–Masson stain. d and e) Axial computed tomography shows biapical pleural thickening and adjacent dense consolidation, architectural distortion, and traction bronchiectasis. A deep sternal notch, platythorax, and posterior deviation of the trachea overlapping the thoracic spine are present.

lung parenchyma to an extent not seen in apical caps. Although most frequently subpleural-predominant, it can also have a more central distribution.

The radiological hallmark of PPFE is biapical subpleural parenchymal fibrosis with pleural thickening (figure 7c and d) [108, 109, 115–117, 123, 126, 130–136]. Fibrosis manifests as sharply demarcated dense consolidation, traction bronchiectasis, architectural distortion and reticulation in a subpleural distribution, although disease can be more widespread. PPFE is differentiated from apical caps by upper lobe volume loss as well as involvement of the anterior and posterior upper lobes, major fissures, and middle and lower lobes. PPFE is included as an interstitial pattern, but also has substantial component within alveoli and distal airways (box 5).

Lymphoid interstitial pneumonia

LIP is part of the spectrum of reactive pulmonary lymphoid hyperplasia. LIP is very rarely idiopathic and mostly occurs secondary to CTD (especially Sjögren syndrome, systemic lupus erythematosus, and rheumatoid arthritis), immunodeficiency, chronic infection (*e.g.* human immunodeficiency virus, Epstein–Barr virus, human T-lymphotropic virus) or other systemic immune disorders [31, 137–144]. Dysproteinaemia is common, mostly polyclonal hypergammaglobulinemia [137]. Given the rarity of idiopathic LIP [143], extensive clinical, serological, and radiological evaluation is required to exclude secondary LIP.

Histologically, LIP is characterised by a dense diffuse infiltrate of lymphocytes and plasma cells expanding and distorting the alveolar septa, often accompanied by reactive lymphoid follicles in a bronchovascular or

BOX 5 Research priorities for PPFE

- What is the pathogenesis of PPFE?
- What is the incidence and prevalence of idiopathic and secondary PPFE?
- Do secondary causes of PPFE influence prognosis?
- In which patients is a biopsy needed to diagnose idiopathic PPFE?

Downloaded from https://publications.ersnet.org on October 19, 2026 by guest. Please see licensing information on first page for reuse rights.

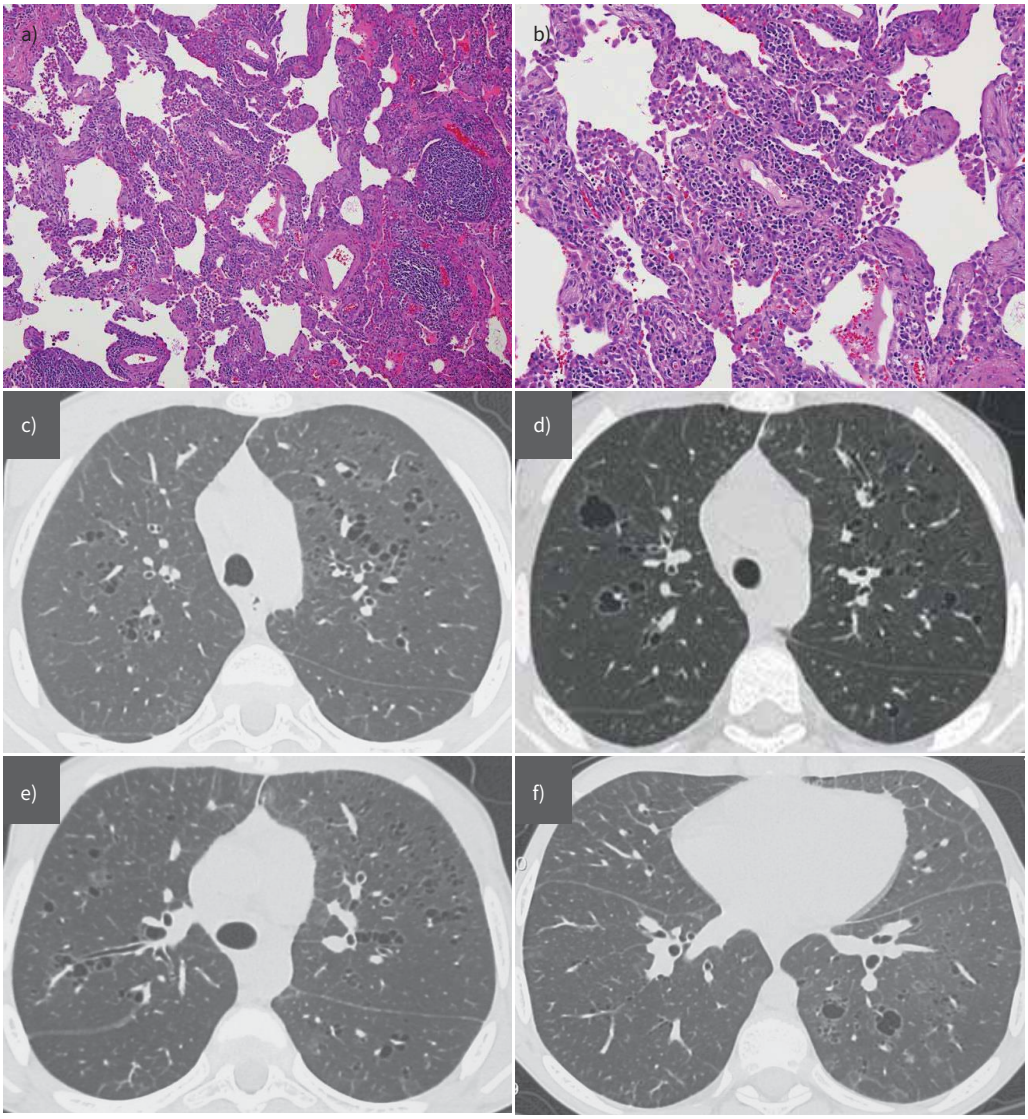

FIGURE 8 Pathological (haematoxylin and eosin stain) and radiological and features of the lymphoid interstitial pneumonia (LIP) pattern. a) Low power view of the histological pattern of LIP shows an alveolar wall interstitium that is diffusely infiltrated with lymphoid cells and a lymphoid aggregate. b) Higher power view shows that the lymphoid cells are lymphocytes with some plasma cells. c–f) Axial computed tomography of the LIP pattern shows multiple cysts in both lungs with mild ground-glass attenuation. Some cysts have a random distribution while others are seen in close contact with bronchovascular bundles.

lymphatic distribution (figure 8a and b) [137, 142, 143, 145, 146]. Interstitial fibrosis is generally minimal or absent. Immunoglobulin (Ig)G-related disease, granulomatous-lymphocytic ILD (GL-ILD), and mucosa-associated lymphoid tissue (MALT) lymphoma enter the differential diagnosis on histology, but the latter usually form one or more solid nodular masses rather than diffuse interstitial infiltration [147]. MALT lymphoma is excluded using a combination of immunohistochemistry and molecular studies. Non-fibrotic NSIP may have similar clinical, radiological and pathological features, but typically has only mild-to-moderate lymphoid infiltration and is rarely cystic. Historical literature reported many LIP cases that would now be reclassified as non-fibrotic NSIP.

CT typically shows bilateral ground-glass opacities that are usually diffuse, but may be patchy, along with small centrilobular and subpleural nodules and bronchovascular thickening (figure 8c–f) [143–148]. Randomly distributed thin-walled cysts occur in ~70% of cases [144–148], although a recent study suggests a lower incidence of cysts in cases with LIP on histology [143]. Lung biopsy is infrequently

Downloaded from https://publications.ersnet.org on October 19, 2026 by guest. Please see licensing information on first page for reuse rights.

BOX 6 Research priorities for LIP

- What is the distinction between LIP and cellular NSIP?
- What is the radiological-pathological correlation of LIP?
- Are there radiologic features sufficiently distinct from other entities in the absence of cysts that can support a diagnosis of idiopathic LIP?
- Is lung biopsy necessary to establish a confident multidisciplinary diagnosis of idiopathic LIP?
- Should patients with LIP be managed as reactive lymphoproliferative disorders, with subtypes according to predominant histological pattern?
- What is the risk of progression to lymphoma in reactive lymphoproliferative disorders?

performed given relatively characteristic imaging findings ± BAL lymphocytosis and frequent presence of an underlying cause (box 6).

Alveolar filling patterns

Alveolar filling patterns are caused by several types of cells and fluid that can abnormally fill the alveoli and distal airways. Common patterns are organising pneumonia, RB-ILD and AMP (table 2), with rare alveolar filling patterns including acute and chronic eosinophilic pneumonia (AEP and CEP, respectively), lipoid pneumonia and pulmonary alveolar proteinosis (PAP) (supplementary table S2). Histopathology is less frequently required for alveolar filling patterns compared to interstitial patterns given the often characteristic clinical, radiological, and laboratory findings.

Organising pneumonia

Organising pneumonia can be idiopathic or "cryptogenic" (COP) or associated with an underlying condition, most commonly post-infectious, CTD, or drug-induced (table 3) [2, 149, 150]. "Cryptogenic" was retained as the term used to reference idiopathic organising pneumonia, given its frequent use in the literature. Diagnosis is often supported by rapid and sometimes complete response to corticosteroids, although with variability across different aetiologies and high potential for recurrence [151–163].

Histologically, organising pneumonia is characterised by polypoid plugs of loose fibroblastic connective tissue within the alveoli and alveolar ducts (figure 9a). Distribution is patchy with preserved lung architecture, although some cases progress to established fibrosis [1, 151, 153, 156, 164–168]. Organising pneumonia can be identified on a transbronchial forceps biopsy, cryobiopsy or transthoracic needle biopsy [154, 156, 169–176]; however, organising pneumonia can also be a nonspecific reaction adjacent to unsampled lesions such as vasculitis, neoplasm, abscess, or infarct. Careful clinical and radiological correlation is critical, particularly with small biopsies to ensure the presentation is consistent with organising pneumonia. Beyond excluding an active infection, BAL typically reveals a lymphocytosis associated with a milder increase in neutrophils and eosinophils, foamy macrophages, and occasional mast cells [152, 154, 155, 161, 164, 172, 173, 177–185].

The characteristic radiological finding of organising pneumonia is subpleural and/or peribronchial consolidation or ground-glass opacity, occasionally presenting as a focal mass or nodules with an air-space pattern (figure 9b) [150, 151, 168, 173, 179, 186–193]. The abnormality may spare specific anatomical regions, resulting in a variety of patterns (*e.g.* reverse halo or perilobular thickening) (figure 9c–f). Organising pneumonia can be migratory on serial imaging. Ancillary CT features (*e.g.* tree-in-bud opacities, cavitations) and histological findings (giant cells, alveolar haemorrhage) can suggest a specific underlying aetiology (*e.g.* infection, vasculitis, drug exposure).

Acute fibrinous and organising pneumonia (AFOP) is a histological pattern that can be seen in patients who present with a spectrum of clinical and radiological manifestations ranging from organising pneumonia to DAD (figure 10a and b) [150, 169, 194–198]. Most cases of AFOP are also secondary, manifesting as predominantly patchy mass-like lesions or ground-glass opacities on imaging and prominent intra-alveolar fibrin forming balls with varying amounts of organising pneumonia on histology [199]. Organising pneumonia can also be a component of a mixed pattern of lung injury, often with NSIP, or can progress from typical organising pneumonia to a fibrotic phase more characteristic of NSIP [42, 200]. In this situation, classification as a combination of fibrotic NSIP and organising pneumonia is preferred histologically to "fibrosing organising pneumonia". The term "cicatricial organising pneumonia" (figure 10c–f), may also be used to describe organising pneumonia when the polypoid plugs comprise dense established fibrous tissue, sometimes with dendriform ossification, and often in a perilobular

Downloaded from https://publications.ersnet.org on October 19, 2026 by guest. Please see licensing information on first page for reuse rights.

TABLE 3 Features and differential diagnoses for subpatterns of organising pneumonia

	Histological findings	CT features		Time- and space-related changes		Differential diagnoses
		Diffuse/ multifocal	Focal	Diffuse/multifocal	Focal	
Organising pneumonia	Polypoid plugs of loose connective tissue in alveoli, alveolar ducts ± respiratory bronchioles Chronic interstitial inflammation is mild in COP and more prominent in secondary organising pneumonia ± Ancillary findings associated with secondary aetiologies	Consolidations Ground-glass Perilobular pattern Halo sign Reverse halo (atoll) sign Mixed	Nodules Mass-like lesions Nodules/masses with halo sign Parenchymal bands	Migratory Relapse (especially if disease extent >10%) Lower-lobe predominance Possible sparing patterns (lobular, subpleural sparing, vascular sparing, reverse halo)	Migratory Distribution (peribronchovascular, bronchocentric)	COP Secondary organising pneumonia: CTD Infections Aspiration Neoplastic disorders Immune dysregulation (*e.g.* GVHD, CLAD, CVID) Drug exposure (*e.g.* e-cigarettes, cocaine) Radiation therapy Vasculitis HP
AFOP	Fibrinous intra-alveolar balls Intra-alveolar loose fibrotic plugs Absence of hyaline membranes	Mass-like Ground-glass Nodules		Tendency to coalesce		Idiopathic AFOP Secondary AFOP: Infections Drug toxicity CTD
CiOP	Dense fibrous bands Small dense fibrous nodules forming intraluminal polypoid plugs Dendriform ossification	Ground-glass Consolidation Reticulation Diffuse pulmonary ossification		Distribution: Peribronchial Subpleural Perilobular		Idiopathic CiOP Secondary CiOP: Aspiration Ehlers–Danlos Ulcerative colitis

CT: computed tomography; AFOP: acute fibrinous and organising pneumonia; CiOP: cicatricial organising pneumonia; COP: cryptogenic organising pneumonia; CTD: connective tissue disease; GVHD: graft *versus* host disease; CLAD: chronic lung allograft dysfunction; CVID: common variable immunodeficiency; HP: hypersensitivity pneumonitis.

https://doi.org/10.1183/13993003.00158-2025

Downloaded from https://publications.ersnet.org on October 19, 2026 by guest. Please see licensing information on first page for reuse rights.

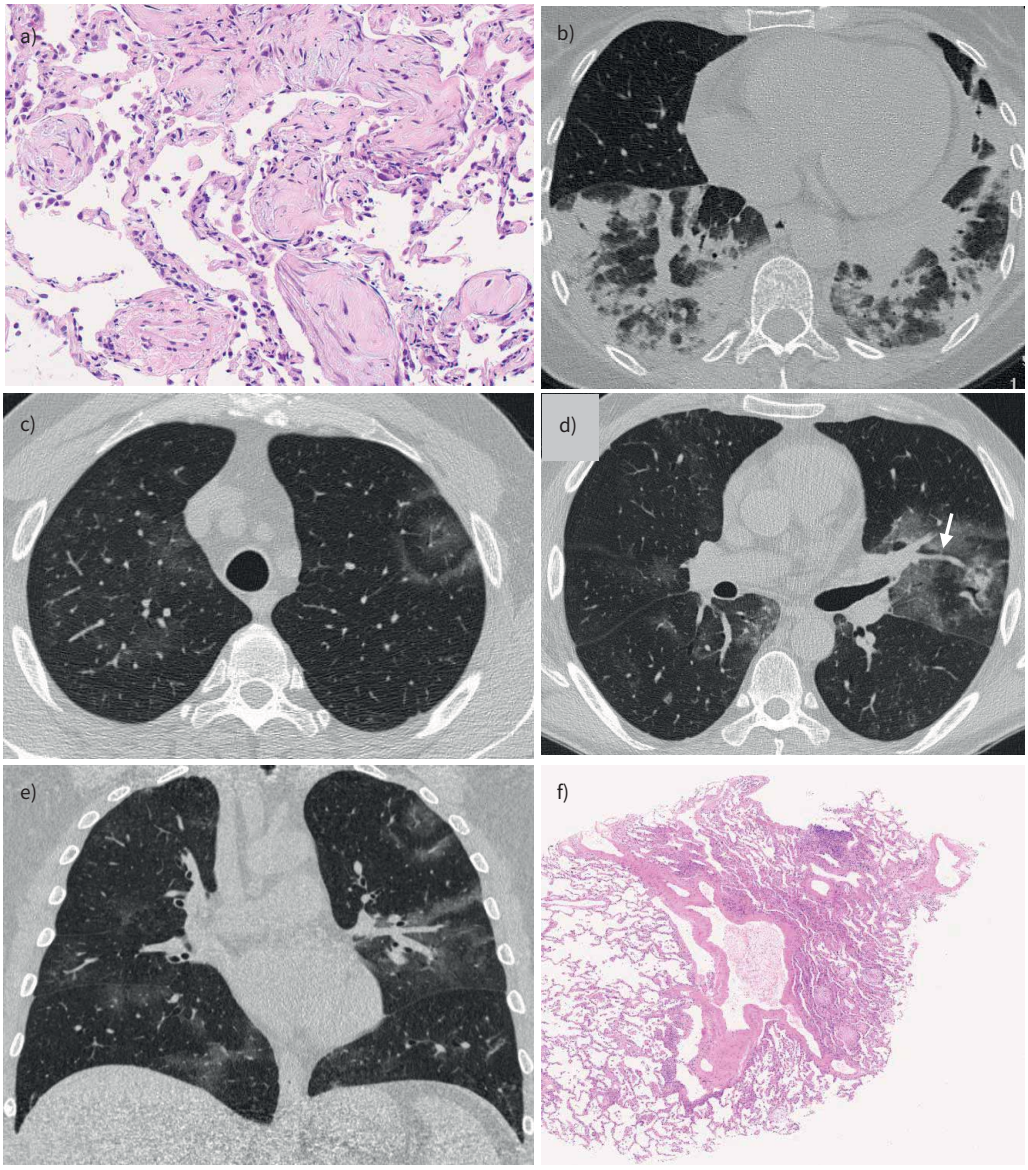

FIGURE 9 Pathological (haematoxylin and eosin stain) and radiological features of the organising pneumonia pattern. a) Lung biopsy of the organising pneumonia pattern shows polypoid intraluminal plugs of loose organising connective tissue in alveolar ducts and alveoli with uniform and patchy distribution. Lung architecture is preserved without interstitial fibrosis. Interstitial inflammation is inconspicuous. b) Axial computed tomography (CT) of organising pneumonia shows consolidation and ground-glass attenuation in both lower lobes with areas of lobular sparing. c and d) Axial and e) coronal CT shows sparing patterns of organising pneumonia with bilateral areas of ground-glass associated with a reverse halo sign in the anterior segment of left upper lobe as well as vascular sparing in the left upper lobe. f) Transbronchial cryobiopsy of organising pneumonia confirming the relationship with veins and lymphatic: a rim of intra-alveolar polypoid plugs of loose organising connective tissue on one side of an interlobular vein (courtesy of Venerino Poletti, University of Bologna, Bologna, Italy).

distribution [166, 167, 200, 201]. Organising pneumonia can also present as a localised solitary mass or combined with non-necrotising granulomatous inflammation; the latter termed by some as "granulomatous organising pneumonia" (box 7) [150].

Respiratory bronchiolitis interstitial lung disease

There is a histological spectrum of disorders characterised by excessive accumulation of macrophages in the alveoli. Patients with predominant features of bronchiolitis are referred to as RB-ILD. Two large cohort

Downloaded from https://publications.ersnet.org on October 19, 2026 by guest. Please see licensing information on first page for reuse rights.

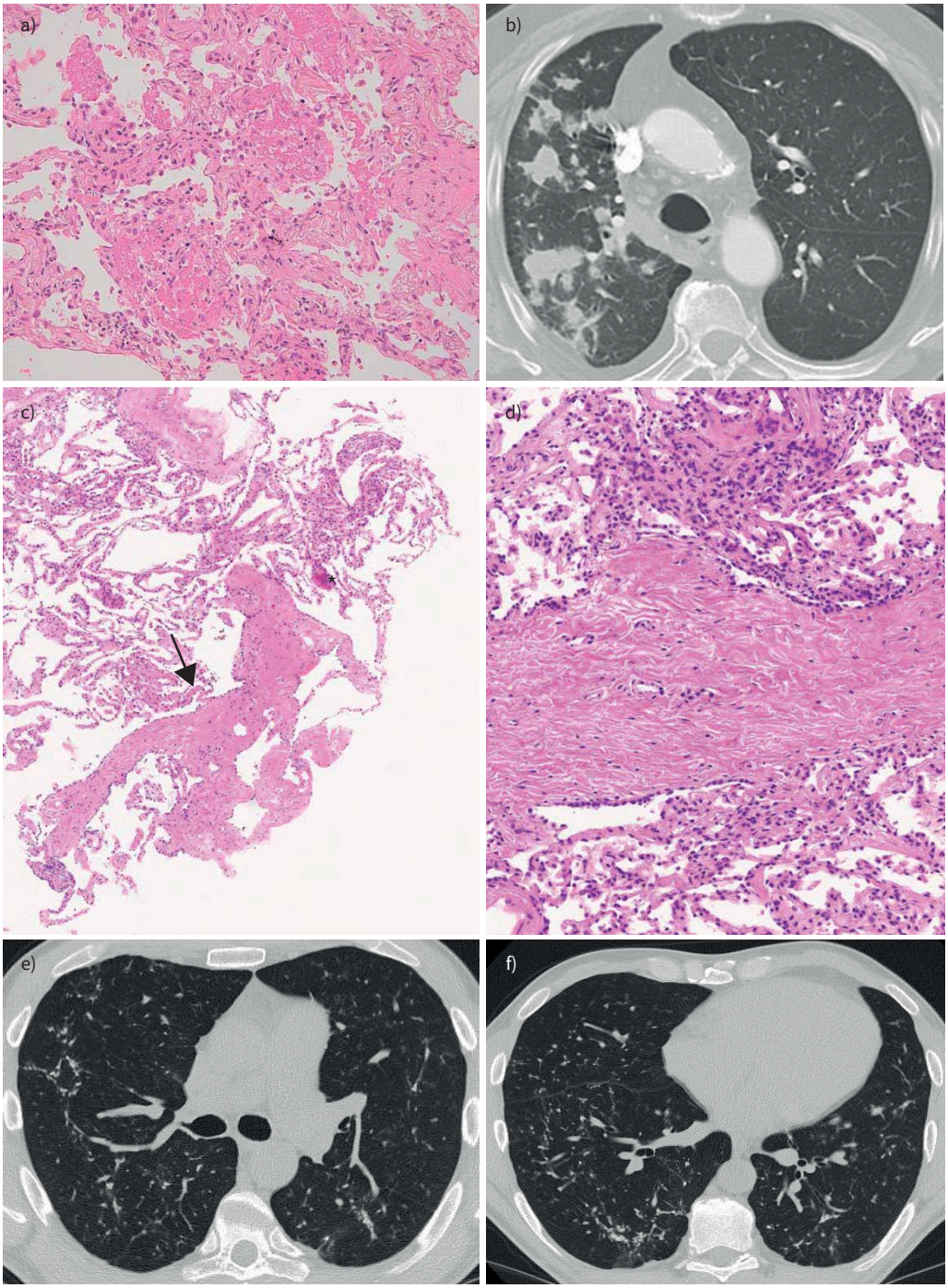

FIGURE 10 Pathological (haematoxylin and eosin stain) and radiological features of organising pneumonia pattern variants. a) Transbronchial cryobiopsy of acute fibrinous organising pneumonia (AFOP) shows balls of fibrin almost completely filling the alveolar spaces with inter-alveolar septae slightly thickened by collagen deposition and scattered inflammatory cells (courtesy of Venerino Poletti). b) Axial computed tomography (CT) of AFOP shows multiple nodules and rounded consolidations in the right lung, with distribution of findings along the bronchovascular bundle. c) Transbronchial cryobiopsy of the cicatricial organising pneumonia (CiOP) pattern shows a polypoid plug rich in densely eosinophilic collagen (arrow) and focus of bone metaplasia (asterisk). d) Higher-power view of organising pneumonia shows the tendon-like appearance of the collagenised intra-alveolar polyp (courtesy of Venerino Poletti, University of Bologna, Bologna, Italy). e and f) Axial CT of CiOP shows mild thickening of the interlobular septa associated with multiple dendriform ossifications mainly in the peripheral and basal lung zones.

Downloaded from https://publications.ersnet.org on October 19, 2026 by guest. Please see licensing information on first page for reuse rights.

BOX 7 Research priorities for organising pneumonia

- In what clinical settings is a biopsy warranted to diagnose organising pneumonia?
- What variables predict relapse of organising pneumonia?
- What induces progression to fibrosis in patients with organising pneumonia?

studies both reported that 93% of cases with a histological pattern of RB-ILD were smoking-related, with a small minority being considered idiopathic [54, 202, 203]. RB is a common incidental histological finding in smokers, which is labelled "RB" when not associated with symptoms or abnormal physiology. Histologically, the fibrosis is patchy, subpleural, and within alveolar walls, consisting of temporally homogenous, pauci-cellular, dense, and eosinophilic collagen causing alveolar wall thickening, although RB-ILD is now rarely biopsied, as imaging features are so well characterised. Distribution is bronchiolocentric in RB-ILD, with respiratory bronchioles, alveolar ducts and peribronchiolar alveoli containing clusters of lightly pigmented macrophages. There may be an associated chronic peribronchiolar inflammatory cell infiltrate with or without mild peribronchiolar and/or alveolar wall fibrosis (figure 11a). Chest imaging shows patchy and poorly defined ground-glass, often in a centrilobular distribution (figure 11b). The presence of lightly pigmented macrophages on BAL is supportive of RB-ILD in the correct clinical and imaging setting and may help exclude other disorders such as non-fibrotic HP.

A pattern of interstitial fibrosis associated with RB-ILD and coexisting emphysema has been described as airspace enlargement with fibrosis (AEF) [204], RB-ILD with fibrosis [205], and smoking-related interstitial fibrosis (SRIF) [206–209]. The consensus of the committee was that "RB-ILD" should be used for the morphological pattern on histology and imaging when macrophage accumulation is the cause of symptoms, with SR-ILD being used as an umbrella term for RB-ILD and other patterns such as AMP (discussed later) when they are caused by exposure to cigarette smoke. RB-ILD and other forms of SR-ILD are frequently incidentally identified in lung cancer resection specimens. Histologically, the fibrosis is patchy, subpleural and within alveolar walls, consisting of temporally homogeneous, pauci-cellular, dense, and eosinophilic collagen causing alveolar wall thickening [204–206, 210]. CT shows

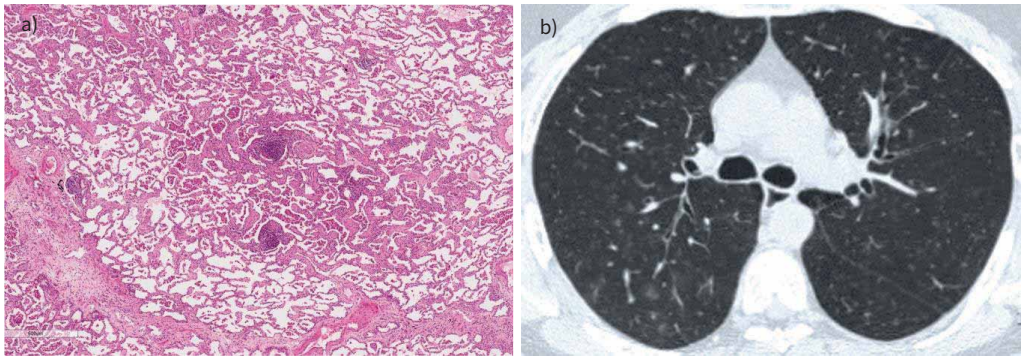

FIGURE 11 Pathological (haematoxylin and eosin stain) and radiological features of the respiratory bronchiolitis-interstitial lung disease (RB-ILD) pattern. a) Lung biopsy of the RB-ILD pattern shows a bronchiolocentric accumulation of pigmented macrophages within a bronchiole and the surrounding alveolar spaces. An excess of alveolar macrophages filling alveoli is the major pathological feature. b) Axial computed tomography of RB-ILD shows scattered centrilobular ground-glass nodules in both upper lobes and in the apical segments of lower lobes. No fibrotic distortion is visible.

BOX 8 Research priorities for RB-ILD

- What is the pathogenesis of RB-ILD?
- What is the relationship of RB-ILD with SRIF and respiratory bronchiolitis with fibrosis?
- What are the potential aetiologies of RB-ILD?
- In what clinical settings is a biopsy warranted to diagnose RB-ILD?

Downloaded from https://publications.ersnet.org on October 19, 2026 by guest. Please see licensing information on first page for reuse rights.

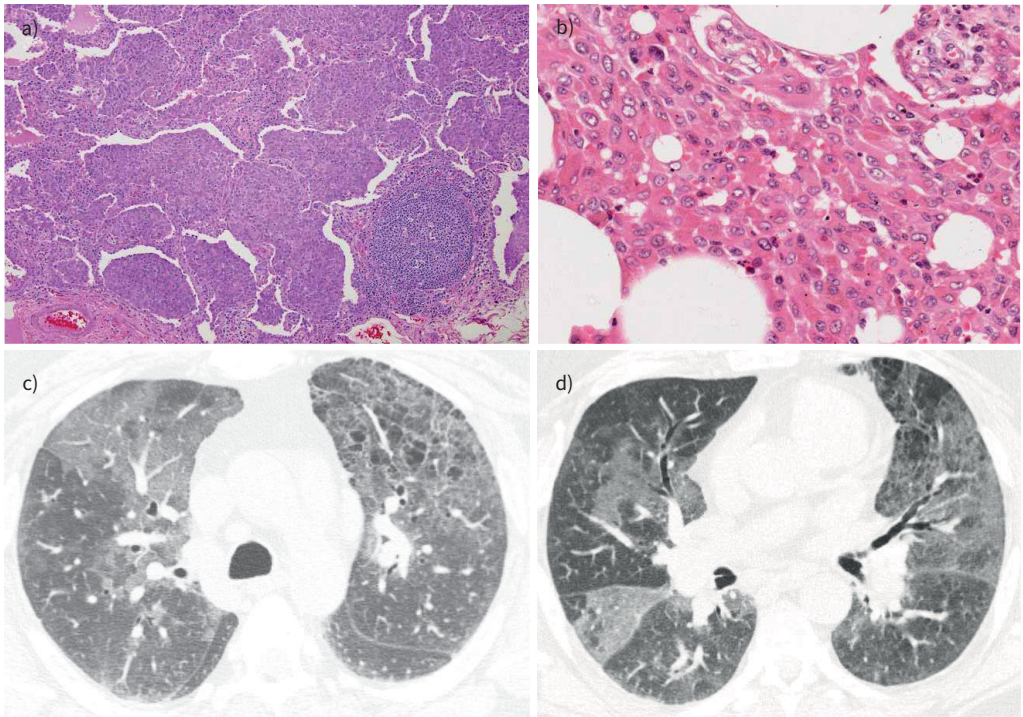

FIGURE 12 Pathological (haematoxylin and eosin stain) and radiological features of the alveolar macrophage pneumonia (AMP) pattern. Lung biopsy of the AMP pattern a) shows diffuse expansion of alveoli by macrophages, associated with b) mild chronic inflammation within the interstitium that includes a germinal centre. An excess of alveolar macrophages filling alveoli is the major pathological feature. The macrophages may show variable pigment accumulation and may be associated with eosinophils. c and d) Axial computed tomography (CT) of AMP shows patchy areas of ground-glass attenuation in both lungs. Associated is a background of paraseptal and centrilobular emphysema and scattered cysts, mainly in the left upper lobe.

prominent cysts that are frequently clustered and confluent, mostly in the upper or mid lower lobes [206, 211, 212]. Features distinguishing AEF or SRIF from UIP include emphysema adjacent to the cystic areas, subpleural cysts where the adjacent lung is spared, heterogeneity of size and shape of the cysts, lack of cysts in the upper lobes, asymmetry of the cystic changes, minimal or no traction bronchiectasis, and lack of ground-glass opacities and/or reticulation around the cysts (box 8) [209].

Alveolar macrophage pneumonia

AMP replaces DIP as the term used to describe excessive widespread accumulation of macrophages within alveoli [58, 213–219]. Most cases of AMP are smoking-related (81% in a systematic review that included 362 cases) [58, 213]; however, AMP can be idiopathic or associated with secondary causes, including surfactant-protein disorders in children, CTD, or occupational dust inhalation [213, 220, 221].

AMP has a diffuse pattern of lung involvement with a uniform distribution within airspaces, where alveolar walls may be fibrotic and variably inflamed, including eosinophils and lymphoid aggregates (figure 12a and b). There is no difference in haemosiderin pigmentation comparing AMP in smokers and nonsmokers; however, small black carbon particles are typically present in the macrophage cytoplasm of smokers [58]. Many patients have features of both RB-ILD and AMP, with these overlapping cases referred to by the predominant pattern. AMP can also coexist with other patterns, such as UIP, and may develop features of NSIP over time [58, 222]. Features of AMP also frequently exist in Langerhans cell histiocytosis [223].

AMP commonly manifests as ground-glass on chest CT (figure 12c and d), but findings may lack specificity [39, 58, 213, 216–218, 223–227]. Ground-glass in AMP is more confluent than in RB-ILD and primarily present in mid and lower lobes with a peripheral predilection, often associated with fine reticulation [213, 228]. Other CT findings may include signs of fibrosis, cysts and emphysema; honeycombing is uncommon [211, 229, 230]. AMP rarely presents with centrilobular nodules (box 9).

Downloaded from https://publications.ersnet.org on October 19, 2026 by guest. Please see licensing information on first page for reuse rights.

BOX 9 Research priorities for AMP

- What is the pathogenesis of AMP?
- What is the relationship of AMP with SRIF and respiratory bronchiolitis with fibrosis?
- What are the potential aetiologies of AMP?
- In what clinical settings is a biopsy warranted to diagnose AMP?
- Is there a genetic basis as to why some smokers develop emphysema/COPD and others develop ILD?

Rare alveolar filling patterns

AEP and CEP are lung-limited disorders characterised by eosinophilic accumulation in distal airways and alveoli, with BAL eosinophilia typically >25% of nucleated cells. AEP develops over days to weeks, and may progress rapidly to respiratory failure [231–236], while CEP typically presents with dyspnoea and cough evolving over weeks to months [237, 238]. Young adult males, often with airflow obstruction and hyperactive airways [237, 239–245], are most often affected and it is often associated with either starting or increasing the amount of cigarette smoking, although other inhalational exposures have been described and some cases remain idiopathic [231–233]. Histologically, AEP typically has features of DAD and/or organising pneumonia with presence of numerous eosinophils [246], while CEP often shows scattered non-necrotising granulomas and rarely granulomas surrounding necrotic eosinophilic microabscesses (supplementary figure S2a–c). Imaging of AEP typically include multifocal and bilateral ground-glass and/or consolidation, septal and bronchovascular thickening, and small bilateral pleural effusions (supplementary figure 2d–f) [234, 247–249]. Imaging of CEP may be indistinguishable from organising pneumonia, including progressive, migratory, and recurrent peripheral and upper lung predominant nonsegmental consolidation and ground-glass opacity [237–239, 242, 250–253]. There may be associated mediastinal lymphadenopathy, septal thickening, centrilobular nodules, and, in more chronic and refractory cases, apical or lower zone peripheral traction bronchiectasis [237, 239–241, 243, 254]. Peripheral blood and BAL cellular differential can be normal or may reveal eosinophilia initially, although with rapid normalisation with corticosteroid therapy [178, 255]. Rapid response of both AEP and CEP to corticosteroids within a few days is highly suggestive (box 10) [232, 234–238, 245, 252, 256, 257].

PAP is a rare disorder (prevalence 7–10 per million) defined by abnormal accumulation of surfactant in the alveoli and distal airways [258–261], generally through reduced granulocyte–macrophage colony-stimulating factor (GM-CSF) or impaired processing of surfactant by alveolar macrophages. PAP typically develops over months to years in the third to fifth decade [262–267] and can occasionally lead to respiratory failure particularly in the context of a haematological malignancy or superimposed infection (most frequently *Nocardia* or non-tuberculous *Mycobacteria*) [268]. Causes of PAP include autoantibodies to GM-CSF (90% of all PAP cases), inhalational exposures (*e.g.* silica, aluminium and titanium), haematological disorders (*e.g.* haematological malignancy, myelodysplastic syndrome, GATA2 deficiency), allogeneic haematopoietic cell transplantation, and some infections [263–265, 269–271]. Fibrosis develops in up to 20% of patients with PAP, mainly with congenital variants, but also occasionally with other causes [272, 273], and is associated with a poor prognosis [274]. Chest imaging typically shows symmetric perihilar ground-glass with inter and intralobular septal thickening as well as subpleural sparing in >80% of cases (supplementary figure S3a) [260, 274–282]. This classic “crazy paving” pattern is more typical of autoimmune and hereditary PAP and is unusual in other causes of PAP [274, 275], in which diffuse ground-glass is more common. Increased levels of serum anti-GM-CSF autoantibodies are present in the autoimmune form, but can also occur with inorganic toxin exposure [283]. BAL is milky and opaque only in advanced disease [262, 284–286]. Histopathology is typically not necessary or recommended in previous guidelines [287], but when performed will show alveolar accumulation of amorphous, amphophilic material (supplementary figure S3b) [262, 267, 278, 281, 288]. Foamy macrophages with cytoplasmic inclusions, cholesterol crystals, scattered hyperplastic type II pneumocytes, and mature lymphocytes are also typically present. The interstitial space is mostly normal, with lymphocytic infiltrate absent or minimal (box 11) [259].

BOX 10 Research priorities for eosinophilic pneumonia

- What is the relationship between eosinophilic pneumonia and other eosinophilic lung diseases?
- In what clinical settings is a biopsy warranted to diagnose eosinophilic pneumonia?
- What variables predict relapse of eosinophilic pneumonia?

Downloaded from https://publications.ersnet.org on October 19, 2026 by guest. Please see licensing information on first page for reuse rights.

BOX 11 Research priorities for PAP

- What is the pathogenic role of infections in PAP?
- How frequently does PAP develop progressive fibrosis and what variables predict this progression?
- What treatments should be considered in PAP that progresses despite first-line therapy?

Lipoid pneumonia is subcategorised as exogenous when due to aspiration or inhalation of foreign material, or endogenous when a consequence of accumulation of lipid created by cells within the body. Despite substantial variability and the fact that some causes of lipoid pneumonia are not typically considered interstitial pneumonias, similarities in clinical presentation justify summarising relevant data irrespective of underlying cause. Lipoid pneumonia most frequently has a chronic presentation, often with mild respiratory symptoms, but can also present acutely [289]. Imaging findings of exogenous lipoid pneumonia depend on acuity, volume, and type of lipid inhalation, with animal fat causing an intense inflammatory reaction and mineral or vegetable oil stimulating a foreign body reaction. Exogenous lipoid pneumonia causes middle- and lower-lobe-dependent or peribronchiolar consolidation and ground-glass opacity, irregular nodules, or masses of low or fat attenuation (−30 to −150 HU) (supplementary figure S4a and b) [289–298]. Other findings include septal thickening, "crazy paving", lymphadenopathy, thin-walled cysts, avidity on 2-fluoro-2-deoxy-D-glucose-positron emission tomography (PET), and pleural effusion in acute cases. Lipoid pneumonia is often localised when due to airway obstruction or inhalation/aspiration, but may be diffuse, especially when associated with immunological diseases and inborn errors of metabolism [290, 299]. Lung biopsy is infrequently required to diagnose lipoid pneumonia given its characteristic imaging features. When performed, histology of exogenous lipoid pneumonia comprises larger and more variably sized droplets in the interstitium, often associated with histiocytic giant cells, while endogenous lipoid pneumonia comprises macrophages with foamy cytoplasm filling alveoli (supplementary figure S4c and d) [289, 295, 299, 300]. Lipid-laden macrophages can be present within the interstitium in endogenous lipoid pneumonia, but is more common in exogenous lipoid pneumonia. Interstitial fibrosis may also be present. BAL is similarly not always required for diagnosis (box 12).

Combined patterns

Interstitial pneumonia can present with a combination of multiple distinct patterns (table 4 and figure 13). Up to 50% of patients with findings suggestive of PPFE also have a UIP pattern [117, 301, 302], and features of PPFE commonly coexist in IPF [111, 114, 124, 125, 303, 304], typically being labelled and treated as IPF. PPFE and UIP can coexist with other patterns in a variety of diagnoses (*e.g.* CTD-ILD, HP), with their presence usually portending a worse prognosis [111, 114, 119, 124, 136, 302–311]. A combination of NSIP and organising pneumonia is reported in up to 60% of patients with idiopathic inflammatory myositis [312–318]. ILD can also be combined with non-ILD abnormalities, for example including superimposed chest infections, pleural or airway abnormalities in patients with CTD-ILD, or combined pulmonary fibrosis and emphysema [319, 320]. Additional combinations include AEF (a combination of emphysema and other interstitial pneumonias, mainly smoking-related ILD), granulomatous organising pneumonia, GL-ILD (a combination of granulomatous inflammation, lymphoid hyperplasia, and sometimes organising pneumonia, mainly due to common variable immunodeficiencies), and combined HP and PAP (often related to immune dysfunction). Combined and atypical patterns are frequently seen in patients with familial pulmonary fibrosis. Patients who have combined patterns are often challenging to diagnose and manage. A careful multidisciplinary evaluation can often reconcile the apparent finding of different patterns being observed in different regions of lung to suggest a unifying diagnosis or can at least identify a dominant pattern that should drive management and prognosis. This is particularly true for patients with UIP as a predominant pattern, which typically drives prognosis when present (box 13) [24].

Unclassifiable ILD

ILD remains unclassifiable in a substantial minority of patients despite a thorough multidisciplinary evaluation, with a systematic review of 1060 patients from 88 studies reporting 11.9% overall prevalence

BOX 12 Research priorities for lipoid pneumonia

- What are the potential aetiologies of endogenous lipoid pneumonia?
- What is the role for BAL in the diagnosis of lipoid pneumonia?
- What is the role of whole-lung lavage in lipoid pneumonia?
- What factors are associated with poor outcomes in lipoid pneumonia?

Downloaded from https://publications.ersnet.org on October 19, 2026 by guest. Please see licensing information on first page for reuse rights.

TABLE 4 Common combined radiological-histological patterns and key clinical differential diagnoses

Dominant and coexisting patterns[#]	Common differential diagnoses
UIP	
NSIP	IPF, CTD-ILD, HP
BIP	HP, CTD-ILD, coexistent airway injury of other cause
PPFE	Combined IPF and PPFE, CTD-ILD
DAD	Acute exacerbation of IPF or other secondary UIP (*e.g.* CTD-ILD)
AMP	IPF + smoking-related ILD
NSIP	
UIP	IPF, CTD-ILD, HP
Organising pneumonia	CTD-ILD, post-DAD, inhalation injury, HP, drug reaction
BIP	HP, CTD-ILD
LIP	CTD-ILD, drug-induced, post-viral (HIV, EBV)
PPFE	Idiopathic PPFE, CTD-ILD
BIP	
Organising pneumonia	CTD-ILD, HP
UIP	HP
NSIP	HP, CTD-ILD
LIP	CTD-ILD
PPFE	Idiopathic PPFE
Organising pneumonia	
NSIP	Post-infection, CTD-ILD, inhalation injury, HP, drug reaction
UIP	CTD-ILD, acute exacerbation of IPF
BIP	HP, CTD-ILD

UIP: usual interstitial pneumonia; NSIP: nonspecific interstitial pneumonia; BIP: bronchiolocentric interstitial pneumonia; PPFE: pleuroparenchymal fibroelastosis; DAD: diffuse alveolar damage; AMP: alveolar macrophage pneumonia; LIP: lymphoid interstitial pneumonia; IPF: idiopathic pulmonary fibrosis; CTD-ILD: connective tissue disease-associated interstitial lung disease; HP: hypersensitivity pneumonitis; EBV: Epstein–Barr virus. [#]: only common combined patterns are listed, and additional combinations can exist (*e.g.* BIP + AMP in an active smoker with HP).

and 9.5% prevalence after multidisciplinary discussion [321]. This can occur with incomplete data (*e.g.* no lung biopsy performed), the presence of discordant findings, or truly unclassifiable cases that lack features characteristic of any single diagnosis [322]. An international working group proposed that unclassifiable ILD be defined as the inability to provide a specific diagnosis with >50% confidence after a comprehensive multidisciplinary review, whether an adequate biopsy was obtained or not [15]. Patients with ⩾90% and 51–89% diagnostic confidence were considered to have "confident" and "provisional" diagnoses, respectively. Despite the challenges in studying such a heterogeneous population, unclassifiable ILD should be a major focus of studies examining novel diagnostic tests given the unmet needs of this population (box 14).

Molecular advances in interstitial pneumonia

Better tools are needed to inform the diagnosis, management, and prognosis of interstitial pneumonia. In this section, we summarise clinically useful and available molecular tests, as well as others that require further study (table 5 and supplementary table S4).

Genetics

~25% of patients with familial pulmonary fibrosis have pathogenic variants in either surfactant-related or telomere biology-related genes, including *RTEL1*, *PARN*, *TINF2*, *TERT*, and *TERC* [323–331], while genes such as *HLA-DRB1*15* connect IPF and other interstitial pneumonias to the immune system [332, 333]. Abnormal genes are also implicated in up to 10% of sporadic cases [334–339]. with integrative analyses estimating pulmonary fibrosis heritability at 28% [340, 341]. The most impactful and consistently replicated single nucleotide polymorphism (SNP) is the *MUC5B* promoter SNP (*rs35705950*), where one copy of the *MUC5B* T risk allele increases pulmonary fibrosis risk by six-fold and two copies by 20-fold [342–349]. The consistently high prevalence of the *MUC5B* promoter polymorphism in sporadic IPF-UIP, HP-UIP, and rheumatoid arthritis-associated UIP suggests a potential overarching genetic basis for these diseases [342, 343, 348, 350–352]; however, this variant is rarer and therefore of less certain clinical utility in Asian and African-American populations [349, 353, 354]. Notably, genetic testing can clarify pulmonary fibrosis aetiology in select patients, particularly in those with a familial predisposition [355],

Downloaded from https://publications.ersnet.org on October 19, 2026 by guest. Please see licensing information on first page for reuse rights.

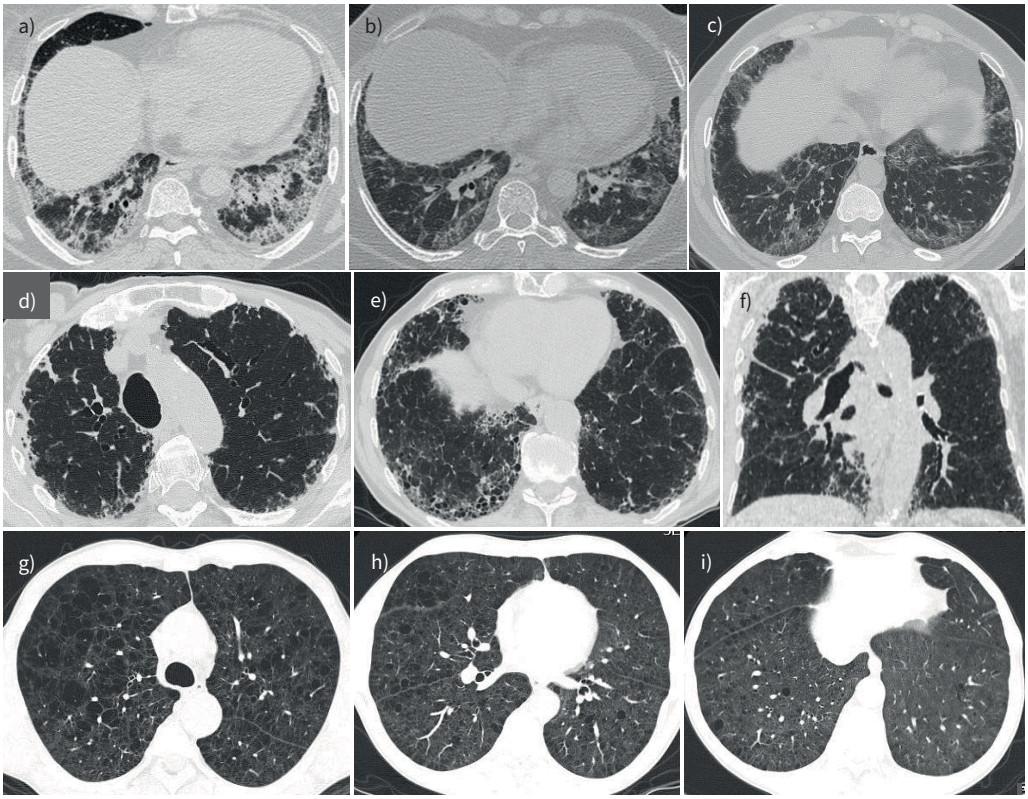

FIGURE 13 Radiological features of combined patterns. a–c) Axial computed tomography (CT) shows a combination of nonspecific interstitial pneumonia (NSIP) and organising pneumonia. a) Axial CT in a patient with antisynthetase syndrome at baseline shows features of both NSIP and organising pneumonia, with ground-glass attenuation and bilateral consolidation in a peribronchovascular and subpleural distribution. Serial CTs at b) 2 and c) 7 years following initiation of immunomodulatory treatment show reduced consolidation with residual ground-glass and mild fibrosis that is more typical of NSIP. d–f) Axial CT shows a combination of pleuroparenchymal fibroelastosis (PPFE) in the upper lobes and usual interstitial pneumonia (UIP) in the lower lobes. d) Axial CT of PPFE shows mild fibroelastosis in both upper lobes, characterised by dense pleural and subpleural fibrosis. e) The lower lobes show a UIP pattern, characterised by subpleural honeycombing and peripheral traction bronchiectasis, while f) the coronal view confirms the combination of patterns. g–i) Axial CT of hypersensitivity pneumonitis (HP) with emphysema in a never-smoker with a strong history of organic dust exposure and lymphocytosis on bronchoalveolar lavage showing both extensive emphysema and scattered thin-walled cysts with centrilobular ground-glass.

BOX 13 Research priorities for combined patterns

- What is the prevalence of different combined patterns?
- Is the biology of combined patterns similar to each individual pattern?
- Is the prognosis of combined patterns the same as the more progressive of the individual patterns?

BOX 14 Research priorities for unclassifiable ILD

- What is the definition of unclassifiable ILD?
- What workup is necessary prior to assigning a diagnosis of unclassifiable ILD?
- How and how frequently should patients with unclassifiable ILD be re-screened for CTD?
- What variables predict progression of unclassifiable ILD?

Downloaded from https://publications.ersnet.org on October 19, 2026 by guest. Please see licensing information on first page for reuse rights.

TABLE 5 Molecular biomarkers in interstitial pneumonia

	Pathophysiology	Clinical accessibility	Clinical value		
			Diagnostic	Prognostic	Therapeutic
Genetic					
MUC5B rs35705950	Risk allele linked to increased pulmonary fibrosis susceptibility, but slower progression rate	Variably accessible	Unclear	Unclear	Unclear
Telomere-related genes (*TERT, TERC, RTEL1, PARN, DKC1, NAF1, ZCCHC8*)	Telomere-related gene variants linked to increased pulmonary fibrosis risk and rapid disease progression	Variably accessible	Potential value	Potential value	Unclear
Surfactant-related genes (*SFTPC, SFTPA1*, *SFTPA2*)	SRG variants linked to increased pulmonary fibrosis risk and to lung cancer	Variably accessible	Potential value	Unclear	Unclear
Other gene loci (including *DSP, KIF15, HLA-DRB1*)	Polymorphisms in these genes linked to increased pulmonary fibrosis risk	Variably accessible	Unclear	Unclear	Unclear
Short telomeres/telomeropathies					
Leukocyte telomere length	Leukocyte telomere length attrition associated with increased ILD susceptibility and rapid progression rate	Variably accessible	Potential value	Potential value	Emerging value in guiding post-lung transplant and ILD pharmacotherapy
Short telomere syndromes (including dyskeratosis congenita, Hoyeraal–Hreidarsson syndrome)	Clinical manifestation often at younger age, show Mendelian inheritance, have multiorgan involvement	Accessible	Potential value	Unclear	Unclear
Transcriptomic RNA signatures					
Lung biopsy-based Envisia Genomic Classifier	Integrates gene expression profiling with machine learning algorithms to recognise the genomic signature of a UIP pattern	Accessible in North America and Europe	Strengthens UIP diagnosis, but clinical utility unproven	Unclear	Unclear
Peripheral blood-based 52-gene RNA signature	Specific set of 52 genes whose combined expression pattern is indicative of IPF	Unclear	Unclear	Unclear	Unclear
Serum/plasma-based antibody panels					
Autoimmune serology (including ANA, dsDNA, anti-Sm, ACA, anti-Scl-70, anti-RNA polymerase III, anti-Jo-1, anti-MDA5, RF, anti-CCP, SS-A, SS-B, anti-RNP, ANCA, anti-U1 RNP, anti-PL-12 and anti-PL-7, anti-GM-CSF)	Identify the presence of discrete autoantibodies that target protein, nuclear or other cellular components which aid the diagnosis of specific autoimmune diseases	Accessible	Strengthens diagnosis of specific subtypes of CTD-ILD	Potential value	May guide choice of therapy
HP	Serum IgG testing against HP-associated antigens. Suboptimal sensitivity and specificity	Accessible	Positive test may support HP exposure	Unclear	Unclear
Other serum-/plasma-based protein markers					
Proteomics/specific proteins (including MMP-7, CCL18, SP-D, CA-125, CA19-9, KL-6, MMP-1, MMP-8, TGF-β, PDGF)	Tissue-derived glycoproteins, enzymes, and protein signatures linked to various pulmonary processes including innate immunity, tissue remodelling, extracellular matrix turnover and fibrosis	Variably accessible	Unclear	Unclear	Unclear
Inflammatory/immunological markers (CRP, ESR)	Acute-phase protein and proinflammatory markers that play pivotal roles in immune, autoimmune and inflammatory disorders	Globally accessible	Positive markers may support specific interstitial pneumonia diagnoses	Extent of positivity may predict outcomes (*e.g.* CRP)	May guide therapeutic response

ANA: antinuclear antibodies; MDA: melanoma differentiation-associated gene; RF: rheumatoid factor; CCP: cyclic citrullinated peptide; ANCA: antinuclear cytoplasmic antibodies; GM-CSF: granulocyte–macrophage colony-stimulating factor; MMP: matrix metalloproteinase; SP: surfactant-protein; CA: cancer antigen; KL: Krebs von den Lungen; TGF: transforming growth factor; PDGF: platelet-derived growth factor; CRP: C-reactive protein; ESR: erythrocyte sedimentation rate; SRG: surfactant-related gene; ILD: interstitial lung disease; UIP: usual interstitial pneumonia; IPF: idiopathic pulmonary fibrosis; CTD: connective tissue disease; Ig: immunoglobulin.

https://doi.org/10.1183/13993003.00158-2025

Downloaded from https://publications.ersnet.org on October 19, 2026 by guest. Please see licensing information on first page for reuse rights.

and provide prognostic insights, as familial cases often exhibit a more aggressive disease course [355, 356]. However, the limited diversity of populations enrolled in genetic studies impedes a comprehensive understanding of interstitial pneumonia genetics [357], highlighting the need for more inclusive research [349, 355, 358–360].

Transcriptomics

Both bulk and single-cell transcriptomic analyses demonstrate striking differences in lung tissue between IPF and age-matched controls [361, 362], findings that are reinforced by microarray analyses comparing transcriptomic profiles in IPF, idiopathic NSIP, and fibrotic HP [363, 364]. The Envisia genomic classifier (Veracyte, South San Francisco, CA, USA) uses a transcriptomic signature to help distinguish UIP from other interstitial pneumonias [365], showing 88% specificity (70–98%) and 70% sensitivity (47–87%) using lung tissue from transbronchial forceps biopsies [366]. Adding CT appearance data improves the classifier's performance [367]; however, it cannot differentiate different causes of UIP or among various non-UIP patterns [368–370]. Whole-blood transcriptomic profiles similarly distinguish patients with IPF from healthy volunteers [371]. A circulating transcriptomic signature of 52 gene transcripts predicts IPF prognosis [372], a finding replicated across five independent cohorts [373]. These and other molecular discoveries have revealed novel therapeutic targets, identified distinct IPF subtypes [374–377], highlighted the critical role of noncoding RNAs [378, 379], and linked genetic alterations to specific tissue changes [380–383]; however, these tools are not yet clinically available and it is unknown whether these findings predict response to potential therapies.

Telomere length

Telomeres, the DNA sequences at chromosome ends, help prevent DNA damage response [384, 385]. Ageing is associated with telomere attrition in various tissues [386], which is accentuated in patients with pathogenic telomere-related gene variants [355, 358]. When critically shortened (defined as <10th percentile for age), telomeres lose their protective shelterin protein complex cap, eliciting a DNA damage response and consequent senescence reprogramming. Peripheral blood leukocyte telomere length (PBL-TL) is critically shortened in substantial proportions of patients with IPF [331, 387–392], fibrotic HP [343, 351, 387, 390], idiopathic NSIP [387, 388, 390], interstitial pneumonia with autoimmune features [331, 387], various CTD-ILDs [331, 393, 394] and unclassifiable ILD [395]. PBL-TL <10th percentile reliably predicts worse survival and forced vital capacity decline in a variety of ILDs [331, 337, 343, 351, 387–389, 391–393, 396]. Short PBL-TL suggests less potential benefit and greater risk of harm from immunosuppressive medications in IPF, fibrotic HP and unclassifiable ILD [389, 395, 397]. Short telomeres also increase risk of infection and haematological complications post-lung transplantation [398–401].

Serum and plasma-based antibody panels

Antinuclear antibodies (ANA), rheumatoid factor, anti-cyclic citrullinated peptide, antinuclear cytoplasmic antibodies, and myositis antibodies are used as initial screening tests for CTD, with additional antibodies considered in selected populations or with positive screening results of unclear significance [402]. Some autoantibodies also predict prognosis (*e.g.* anti-melanoma differentiation-associated gene (MDA)-5 predicts increased risk of disease progression and more resistant treatment response in dermatomyositis-associated ILD) [403–405]. Despite their utility in suggesting a CTD, circulating autoantibodies are present without obvious clinical significance in up to a third of IPF patients and some patients with fibrotic HP [406–410].

Although ANA positivity increases with age and can be detected in up to 20–25% of healthy individuals aged >60 years, most cases, particularly those with low titres, are not clinically meaningful and are unlikely to reflect underlying autoimmune disease [411, 412]. Coronavirus disease 2019 (COVID-19) was also associated with more frequent ANA positivity, with many of these cases similarly not thought to be clinically meaningful [413]. However, recent evidence suggests that the rise in anti-MDA5 autoimmunity and cases of rapidly progressive ILD during the COVID-19 pandemic may reflect a distinct immunopathological response, potentially triggered by severe acute respiratory syndrome coronavirus 2 infection or vaccination, underscoring the clinical importance of context-specific autoantibody interpretation [414–416].

Serum testing for antigen-specific antibodies is often used in the evaluation of possible HP [25, 33]. Most commercially available assays detect IgG antibodies against inciting HP antigens, primarily targeting a panel of common mould and avian antigens. Although antigen-specific IgG can confirm exposure, there is limited clinical value due to the variable sensitivity and specificity, lack of standardised methodology, and challenges in interpretation [34, 417–420]. Consequently, while serum IgG may provide supportive data in some situations, testing is not recommended as a standalone test for HP confirmation [25, 33].

Downloaded from https://publications.ersnet.org on October 19, 2026 by guest. Please see licensing information on first page for reuse rights.

BOX 15 Overarching research priorities for all interstitial pneumonias

- Does photon-counting CT provide superior diagnostic information compared to HRCT?
- What is the role of artificial intelligence in the interpretation of existing diagnostic tools?
- What is the role of genetic testing?
- What molecular tests inform diagnosis, management, and prognosis?
- What is the diagnostic utility of optical coherence tomography?
- In what clinical settings is lung tissue sampling indicated?
- Are targeted interventions available for specific populations?
- What variables predict more rapid progression/relapse?

Protein and proteomic biomarkers

A variety of proteomic biomarkers distinguish IPF from healthy controls and predict prognosis of interstitial pneumonia, including matrix metalloproteinase-7, surfactant protein D, chemokine (C-C motif) ligand 18, cancer antigen 125 (CA125), cancer antigen 19–9 (CA19-9), and Krebs von den Lungen-6 [421–430]. Mortality can be predicted by change in plasma CA125, CYFRA19-9, CA19-9 and collagen degradation biomarkers [421, 423, 424, 431]. Longitudinal sampling of these markers has potential in assessing therapeutic response, most notably with CA125 levels decreasing in patients with IPF who received nintedanib compared to placebo [432]; however, the clinical utility of these markers is currently unclear. Combining individual biomarkers or utilising high-throughput proteomic platforms has led to development of proteomic signatures that may predict disease and support prognostication with greater accuracy, although with the need for further validation to support clinical utility [370, 433–435].

Research priorities

Major uncertainties and research priorities are listed at the end of each section and in supplementary table S4 for the molecular domain. Many of these priorities are focused on personalised medicine, including better understanding of disease biology, identification of noninvasive mechanistically informative diagnostic tests (*i.e.* well-validated biologically relevant biomarkers), development of novel interventions that increasingly target specific biological processes, and the potential for artificial intelligence to improve diagnostic and prognostic accuracy. There are also imaging innovations that may further improve early diagnosis and classification of interstitial pneumonia. Photon counting CT is an emerging advancement in CT imaging technology that provides improved spatial resolution for characterisation of more subtle features at a reduced radiation dose [436–439]. Endobronchial optical coherence tomography (EB-OCT) is a novel, bronchoscopic optical imaging modality that provides rapid volumetric imaging with microscopic resolution (~10 µm) [440]. Recent prospective studies have shown that EB-OCT has high sensitivity and specificity for identification of early UIP in patients with low-confidence clinical-radiological interstitial pneumonia diagnosis, and a strong agreement with surgical lung biopsy for specific interstitial pneumonia patterns [441, 442]. In addition, EB-OCT has potential to investigate new aspects of pathogenesis in interstitial pneumonia, including assessment of small airways that are not resolvable by CT and collagen orientation patterns through birefringence detection [441, 443]. There are also multiple studies examining whether PET scans with labelled markers can provide insight into disease biology or treatment response [444–449]. This has particular relevance for the capture of early efficacy signals for clinical trials, given the ability to directly measure a specific molecular drug target; however, none of these recent studies are clinically relevant at this time.

Major research priorities for the more common interstitial patterns of UIP, NSIP, and BIP include a better understanding of idiopathic cases, generating more robust radiological-pathological correlation (especially for NSIP and BIP), evaluating the diagnostic utility of BAL, and determining whether first-line therapy for non-IPF cases should be antifibrotic or immunomodulatory. For patterns of PPFE and LIP, there is a need to improve our understanding of all aspects of disease, including pathogenesis, epidemiology, diagnosis, and management. For the alveolar disorders, there is a pressing need to better understand biology of organising pneumonia and how to predict relapse or progression to fibrosis. There is similarly a need to better understand the spectrum of disorders encompassed by the categories of RB-ILD and AMP, especially prognostic markers and their optimal management. To support these and other studies, it is necessary for clinicians, researchers, patients, and other stakeholders to use consistent classification approaches and terminology that facilitate integration of existing registries and sharing of data, ideally supporting pragmatic clinical trials in populations that are poorly served through conventional studies. This effort is especially critical for rare interstitial pneumonias that are unable to be studied without international and ideally global collaboration (box 15).

Downloaded from https://publications.ersnet.org on October 19, 2026 by guest. Please see licensing information on first page for reuse rights.

Conclusions

Using a multidisciplinary committee of experts, we have provided an updated framework for the classification of interstitial pneumonia, most notably expanding previous frameworks to go beyond idiopathic entities, clarifying terminology of BIP, idiopathic DAD, and AMP, and subclassifying interstitial pneumonias as either interstitial or alveolar filling disorders. We also provide a comprehensive update on the status of various molecular advances and identify future research priorities. We anticipate that these updates will help guide patient care and direct future research to further improve our understanding of these entities. We further expect that this new knowledge will result in further updates to this document, expanding the entities discussed and ideally including greater biological basis for disease subgrouping.

This document was endorsed by the ERS Executive Committee on 23 July 2025, and by the American Thoracic Society on 10 July 2025.

Published in volume 66, issue 6 of the European Respiratory Journal on 4 December 2025; republished 18 December 2025 to correct a minor typographical error in figure 2.

Committee members are as follows. Pulmonology: Christopher J. Ryerson (co-chair and section lead), Yoshikazu Inoue, Kerri Johannson, Leticia Kawano-Dourado, Yet H. Khor, Katerina Antoniou, Ganesh Raghu, Claudia Ravaglia, Elisabetta A. Renzoni, Athol U. Wells and Marlies S. Wijsenbeek. Radiology: Sara Piciucchi (co-chair and section lead), Takeshi Johkoh, Ella Kazerooni, David Lynch, Martine Remy-Jardin, Amita Sharma, Nicola Sverzellati and Simon L.F. Walsh. Pathology: Andrew G. Nicholson (co-chair and section co-lead), William Travis (co-chair and section co-lead), Wendy A. Cooper, Aurelie Fabre, Lida P. Hariri, Jeffrey Myers and Ryoko Saito-Koyama. Molecular: Ayodeji Adegunsoye (co-chair and section lead), Raphael Borie, Toby M. Maher, Philip L. Molyneaux, Paul Wolters and Soo-Ryum Yang. Patient representatives: Raymond Protti and Una McMillan. Medical librarian: Mimi Doyle-Waters. Ganesh Raghu, David Lynch, Martine Remy-Jardin and Jeffrey Myers requested to not be included as co-authors of the final document given the concerns that are described within the section on bronchiolocentric interstitial pneumonia.

Conflict of interest: C.J. Ryerson reports grants from Boehringer Ingelheim, consultancy fees from Boehringer Ingelheim, Pliant Therapeutics, AstraZeneca, Trevi Therapeutics, Avalyn and Veracyte, payment or honoraria for lectures, presentations, manuscript writing or educational events from Boehringer Ingelheim, payment for expert testimony from Boehringer Ingelheim, and support for attending meetings from Boehringer Ingelheim and Cipla Ltd. A. Adegunsoye reports grants from National Institutes of Health, consultancy fees from Genentech, Inogen, Medscape, Abbvie, PatientMpower, Brainomix and Boehringer Ingelheim, and payment or honoraria for lectures, presentations, manuscript writing or educational events from Boehringer Ingelheim. L.P. Hariri reports grants from Boehringer Ingelheim, Department of Defense and National Institutes of Health, consultancy fees from Boehringer Ingelheim, Pliant Therapeutics, Bioclinica and Abbvie, payment or honoraria for lectures, presentations, manuscript writing or educational events from Boehringer Ingelheim, participation on a data safety monitoring board or advisory board with Boehringer Ingelheim, and leadership roles with ATS, Pulmonary Pathology Society, College of American Pathologists and Pulmonary Fibrosis Foundation. Y.H. Khor reports grants from NHMRC, MRFF, Air Liquide Healthcare and Austin Medical Research Foundation, and leadership roles with the Thoracic Society of Australia and New Zealand, as Board director and Chair for Clinical Care and Resources Sub-Committee. M.S. Wijsenbeek reports grants from The Netherlands Organisation for Health Research and Development, The Dutch Lung Foundation, The Dutch Pulmonary Fibrosis Organization, Sarcoidosis.nl, Boehringer Ingelheim, Hoffman la Roche and AstraZeneca-Daiichi, consultancy fees from AstraZeneca, Avalyn Pharma, Bristol Myers Squibb, Boehringer Ingelheim, Galapagos, Galecto, GSK, Hoffman la Roche, Horizon therapeutics, Kinevant Sciences, Molecure, Nerre Therapeutics, Novartis, PureTech Health, Respivant Science, Sanofi, Trevi and Vicore, payment or honoraria for lectures, presentations, manuscript writing or educational events from Boehringer Ingelheim, CSL Behring, Hoffman la Roche, Novartis and Sanofi, support for attending meetings from Boehringer Ingelheim, GSK and Hoffman la Roche, and leadership roles as secretary of the ILD assembly of the European Respiratory Society, member of the board of the Netherlands Respiratory Society, member of the scientific advisory board of the European Idiopathic Pulmonary Fibrosis and Related Disorders Federation, chair of the educational committee of the European Reference Network for Rare Lung Diseases, and advisory board of the Dutch Lungfibrosis and Sarcoidosis Patient Associations. A.U. Wells reports consultancy fees from Veracyte and Hoffmann-La Roche, payment or honoraria for lectures, presentations, manuscript writing or educational events from Boehringer Ingelheim, Hoffmann-La Roche and Veracyte, travel support from Boehringer Ingelheim, and a leadership role with WASOG as President. A. Sharma reports grants from Boehringer Ingelheim, Department of Defense, aTyr and the National Institutes of Health, consultancy fees from AmGen and Eli Lilly, payment or honoraria for lectures, presentations, manuscript writing or educational events from NYU, Pulmonary Care and Research Collaborative, support for attending meetings from Apollo Radiology International, NYU, patents planned,

Downloaded from https://publications.ersnet.org on October 19, 2026 by guest. Please see licensing information on first page for reuse rights.

issued or pending (PCT/US2023/076749 – System and method for control of ionizing radiation dose in medical applications using synthetic localisers), and a leadership role with American College of Radiology. K. Antoniou reports payment or honoraria for lectures, presentations, manuscript writing or educational events from Boehringer Ingelheim, Roche, GSK, AZ, Chiesi and Menarini, support for attending meetings from Chiesi, AZ and Boehringer Ingelheim, participation on a data safety monitoring board or advisory board with BI, Roche and GSK, and leadership roles with ERS head of Assembly 12 and ERS-EULAR CTD-ILD Guideline Chair. R. Borie reports consultancy fees from Boehringer Ingelheim, Ferrer and Sanofi, payment or honoraria for lectures, presentations, manuscript writing or educational events from Boehringer Ingelheim, and support for attending meetings from Boehringer Ingelheim. Y. Inoue reports grants from Japanese Ministry of Health, Labor, and Welfare, consultancy fees from Boehringer Ingelheim, Roche, Galapagos, Shionogi, Taiho, Kyorin Pharmaceutical, Tanabe Mitsubishi, Mochida, Savara, CSL Behring, Vicore Pharma AB and NobelPharma, payment or honoraria for lectures, presentations, manuscript writing or educational events from Boehringer Ingelheim, Shionogi, Kyorin Pharmaceutical, GSK, AstraZeneca and NobelPharma, and participation on a data safety monitoring board or advisory board with Boehringer Ingelheim, Roche, Taiho, Kyorin Pharmaceutical, Savara, CSL Behring and Vicore Pharma AB. K. Johannson reports grants from University Hospital Foundation and Three Lakes Foundation, consultancy fees from Boehringer Ingelheim, Pliant Therapeutics, Hoffman La Roche and Brainomix, payment or honoraria for lectures, presentations, manuscript writing or educational events from Boehringer Ingelheim and Abbvie, support for attending meetings from Boehringer Ingelheim, participation on a data safety monitoring board or advisory board for the PFOX trial, and stock (or stock options) with Thyron SAB. L. Kawano-Dourado reports grants from Brazilian Ministry of Health (PROADI-SUS), Boehringer Ingelheim and Bristol-Myers-Squibb, consultancy fees from Boehringer Ingelheim, payment or honoraria for lectures, presentations, manuscript writing or educational events from Boehringer Ingelheim, participation on a data safety monitoring board or advisory board with SARAVA, and receipt of equipment, materials, drugs, medical writing, gifts or other services from Fisher & Paykel. T.M. Maher reports consultancy fees from Boehringer Ingelheim, Hoffmann-La Roche/Genentech, Abbvie, Amgen, AstraZeneca, Bayer, Bristol-Myers Squibb, CSL Behring, Galapagos, Galecto, GlaxoSmithKline, IQVIA, Pfizer, Pliant, PureTech, Sanofi, Theravance, Trevi and Vicore, participation on a data safety monitoring board or advisory board with Fibrogen, Blade Therapeutics and Nerre, and stock or stock options from Qureight. P.L. Molyneaux reports grants from AstraZeneca, GSK, Asthma & Lung UK, and Action for Pulmonary Fibrosis, consultancy fees from Hoffman-La Roche, Boehringer Ingelheim, AstraZeneca, Trevi, Qureight and Endeavour, payment or honoraria for lectures, presentations, manuscript writing or educational events from Boehringer Ingelheim and Hoffman-La Roche, participation on a data safety monitoring board or advisory board with United Therapeutics; and stock (or stock options) with Qureight. S.L.F. Walsh reports grants from Boehringer Ingelheim, NIHR and Galapagos, consultancy fees from Boehringer Ingelheim, Hoffmann-La Roche, Galapagos, Open Source Imaging consortium, Puretech, Pliant, Oncorendi Therapeutics and FLUIDDA, payment or honoraria for lectures, presentations, manuscript writing or educational events from Boehringer Ingelheim, participation on a data safety monitoring board or advisory board with Boehringer Ingelheim and Hoffmann-La Roche, and stock or stock options from Qureight Ltd. P. Wolters reports grants from Boehringer Ingelheim, National Institutes of Health, Hoffmann-La Roche, Sanofi and Pliant Therapeutics, and payment or honoraria for lectures, presentations, manuscript writing or educational events from Boehringer Ingelheim. A.G. Nicholson reports consultancy fees from Galapagos, Medical Quantitative Image Analysis, Roche and Boehringer Ingelheim, and payment or honoraria for lectures, presentations, manuscript writing or educational events from Boehringer Ingelheim and Up to Date. The remaining authors have no potential conflicts of interest to disclose.

References

1 American Thoracic Society/European Respiratory Society. American Thoracic Society/European Respiratory Society International Multidisciplinary Consensus Classification of the Idiopathic Interstitial Pneumonias. *Am J Respir Crit Care Med* 2002; 165: 277–304.

2 Travis WD, Costabel U, Hansell DM, *et al.* An official American Thoracic Society/European Respiratory Society statement: update of the international multidisciplinary classification of the idiopathic interstitial pneumonias. *Am J Respir Crit Care Med* 2013; 188: 733–748.

3 Raghu G, Remy-Jardin M, Richeldi L, *et al.* Idiopathic pulmonary fibrosis (an update) and progressive pulmonary fibrosis in adults: an official ATS/ERS/JRS/ALAT clinical practice guideline. *Am J Respir Crit Care Med* 2022; 205: e18–e47.

4 Rajan SK, Cottin V, Dhar R, *et al.* Progressive pulmonary fibrosis: an expert group consensus statement. *Eur Respir J* 2023; 61: 2103187.

5 Wolters PJ, Blackwell TS, Eickelberg O, *et al.* Time for a change: is idiopathic pulmonary fibrosis still idiopathic and only fibrotic? *Lancet Respir Med* 2018; 6: 154–160.

6 Wells AU, Brown KK, Flaherty KR, *et al.* What's in a name? That which we call IPF, by any other name would act the same. *Eur Respir J* 2018; 51: 1800692.

7 Churg A, Wright JL, Ryerson CJ. Pathologic separation of chronic hypersensitivity pneumonitis from fibrotic connective tissue disease-associated interstitial lung disease. *Am J Surg Pathol* 2017; 41: 1403–1409.

Downloaded from https://publications.ersnet.org on October 19, 2026 by guest. Please see licensing information on first page for reuse rights.

8 Marinescu DC, Hague CJ, Muller NL, *et al.* Integration and application of radiologic patterns from clinical practice guidelines on idiopathic pulmonary fibrosis and fibrotic hypersensitivity pneumonitis. *Chest* 2023; 164: 1466–1475.

9 Maher TM, Corte TJ, Fischer A, *et al.* Pirfenidone in patients with unclassifiable progressive fibrosing interstitial lung disease: a double-blind, randomised, placebo-controlled, phase 2 trial. *Lancet Respir Med* 2020; 8: 147–157.

10 Behr J, Prasse A, Kreuter M, *et al.* Pirfenidone in patients with progressive fibrotic interstitial lung diseases other than idiopathic pulmonary fibrosis (RELIEF): a double-blind, randomised, placebo-controlled, phase 2b trial. *Lancet Respir Med* 2021; 9: 476–486.

11 Flaherty KR, Wells AU, Cottin V, *et al.* Nintedanib in progressive fibrosing interstitial lung diseases. *N Engl J Med* 2019; 381: 1718–1727.

12 Pugashetti JV, Adegunsoye A, Wu Z, *et al.* Validation of proposed criteria for progressive pulmonary fibrosis. *Am J Respir Crit Care Med* 2023; 207: 69–76.

13 Hambly N, Farooqi MM, Dvorkin-Gheva A, *et al.* Prevalence and characteristics of progressive fibrosing interstitial lung disease in a prospective registry. *Eur Respir J* 2022; 60: 2102571.

14 Khor YH, Farooqi M, Hambly N, *et al.* Patient characteristics and survival for progressive pulmonary fibrosis using different definitions. *Am J Respir Crit Care Med* 2023; 207: 102–105.

15 Ryerson CJ, Corte TJ, Lee JS, *et al.* A standardized diagnostic ontology for fibrotic interstitial lung disease. An International Working Group Perspective. *Am J Respir Crit Care Med* 2017; 196: 1249–1254.

16 Walsh SLF, Lederer DJ, Ryerson CJ, *et al.* Diagnostic likelihood thresholds that define a working diagnosis of idiopathic pulmonary fibrosis. *Am J Respir Crit Care Med* 2019; 200: 1146–1153.

17 Liebow AA. Definition and classification of interstitial pneumonias in human pathology1. *In*: Basset F, Georges R, eds. Alveolar Interstitium of the Lung. Vol 8. Basel, Karger, 1975; pp. 1–33.

18 Carrington CB, Gaensler EA, Coutu RE, *et al.* Natural history and treated course of usual and desquamative interstitial pneumonia. *N Engl J Med* 1978; 298: 801–809.

19 Raghu G, Remy-Jardin M, Myers JL, *et al.* Diagnosis of idiopathic pulmonary fibrosis. An official ATS/ERS/JRS/ALAT clinical practice guideline. *Am J Respir Crit Care Med* 2018; 198: e44–e68.

20 Katzenstein AL, Zisman DA, Litzky LA, *et al.* Usual interstitial pneumonia: histologic study of biopsy and explant specimens. *Am J Surg Pathol* 2002; 26: 1567–1577.

21 Smith ML. The histologic diagnosis of usual interstitial pneumonia of idiopathic pulmonary fibrosis. Where we are and where we need to go. *Mod Pathol* 2022; 35: Suppl. 1, 8–14.

22 Nishimura K, Kitaichi M, Izumi T, *et al.* Usual interstitial pneumonia: histologic correlation with high-resolution CT. *Radiology* 1992; 182: 337–342.

23 Mukhopadhyay S. Usual interstitial pneumonia (UIP): a clinically significant pathologic diagnosis. *Mod Pathol* 2022; 35: 580–588.

24 Flaherty KR, Travis WD, Colby TV, *et al.* Histopathologic variability in usual and nonspecific interstitial pneumonias. *Am J Respir Crit Care Med* 2001; 164: 1722–1727.

25 Raghu G, Remy-Jardin M, Ryerson CJ, *et al.* Diagnosis of hypersensitivity pneumonitis in adults. An official ATS/JRS/ALAT clinical practice guideline. *Am J Respir Crit Care Med* 2020; 202: e36–e69.

26 Jacob J, Bartholmai BJ, Egashira R, *et al.* Chronic hypersensitivity pneumonitis: identification of key prognostic determinants using automated CT analysis. *BMC Pulm Med* 2017; 17: 81.

27 Kim EJ, Elicker BM, Maldonado F, *et al.* Usual interstitial pneumonia in rheumatoid arthritis-associated interstitial lung disease. *Eur Respir J* 2010; 35: 1322–1328.

28 Gulati M, Redlich CA. Asbestosis and environmental causes of usual interstitial pneumonia. *Curr Opin Pulm Med* 2015; 21: 193–200.

29 Selman M, Pardo A, Wells AU. Usual interstitial pneumonia as a stand-alone diagnostic entity: the case for a paradigm shift? *Lancet Respir Med* 2023; 11: 188–196.

30 Chung JH, Cox CW, Montner SM, *et al.* CT Features of the usual interstitial pneumonia pattern: differentiating connective tissue disease-associated interstitial lung disease from idiopathic pulmonary fibrosis. *AJR Am J Roentgenol* 2018; 210: 307–313.

31 Joy GM, Arbiv OA, Wong CK, *et al.* Prevalence, imaging patterns and risk factors of interstitial lung disease in connective tissue disease: a systematic review and meta-analysis. *Eur Respir Rev* 2023; 32: 220210.

32 Zheng B, Marinescu DC, Hague CJ, *et al.* Lung imaging patterns in connective tissue disease-associated interstitial lung disease impact prognosis and immunosuppression response. *Rheumatology* 2024; 63: 2734–2740.

33 Fernández Pérez ER, Travis WD, Lynch DA, *et al.* Diagnosis and evaluation of hypersensitivity pneumonitis: CHEST guideline and expert panel report. *Chest* 2021; 160: e97–e156.

34 Johannson KA, Barnes H, Bellanger AP, *et al.* Exposure assessment tools for hypersensitivity pneumonitis. An official American Thoracic Society workshop report. *Ann Am Thorac Soc* 2020; 17: 1501–1509.

35 Travis WD, Hunninghake G, King TE Jr, *et al.* Idiopathic nonspecific interstitial pneumonia: report of an American Thoracic Society project. *Am J Respir Crit Care Med* 2008; 177: 1338–1347.

36 Cottin V, Donsbeck AV, Revel D, *et al.* Nonspecific interstitial pneumonia. Individualization of a clinicopathologic entity in a series of 12 patients. *Am J Respir Crit Care Med* 1998; 158: 1286–1293.

Downloaded from https://publications.ersnet.org on October 19, 2026 by guest. Please see licensing information on first page for reuse rights.

37 Travis WD, Matsui K, Moss J, *et al.* Idiopathic nonspecific interstitial pneumonia: prognostic significance of cellular and fibrosing patterns: survival comparison with usual interstitial pneumonia and desquamative interstitial pneumonia. *Am J Surg Pathol* 2000; 24: 19–33.

38 Johkoh T, Müller NL, Colby TV, *et al.* Nonspecific interstitial pneumonia: correlation between thin-section CT findings and pathologic subgroups in 55 patients. *Radiology* 2002; 225: 199–204.

39 Tsubamoto M, Müller NL, Johkoh T, *et al.* Pathologic subgroups of nonspecific interstitial pneumonia: differential diagnosis from other idiopathic interstitial pneumonias on high-resolution computed tomography. *J Comput Assist Tomogr* 2005; 29: 793–800.

40 Li X, Chen C, Xu J, *et al.* Nonspecific interstitial pneumonia and usual interstitial pneumonia: comparison of the clinicopathologic features and prognosis. *J Thorac Dis* 2014; 6: 1476–1481.

41 Sumikawa H, Johkoh T, Ichikado K, *et al.* Nonspecific interstitial pneumonia: histologic correlation with high-resolution CT in 29 patients. *Eur J Radiol* 2009; 70: 35–40.

42 Huo Z, Li J, Li S, *et al.* Organizing pneumonia components in non-specific interstitial pneumonia (NSIP): a clinicopathological study of 33 NSIP cases. *Histopathology* 2016; 68: 347–355.

43 MacDonald SL, Rubens MB, Hansell DM, *et al.* Nonspecific interstitial pneumonia and usual interstitial pneumonia: comparative appearances at and diagnostic accuracy of thin-section CT. *Radiology* 2001; 221: 600–605.

44 Lynch DA, Travis WD, Müller NL, *et al.* Idiopathic interstitial pneumonias: CT features. *Radiology* 2005; 236: 10–21.

45 Hartman TE, Swensen SJ, Hansell DM, *et al.* Nonspecific interstitial pneumonia: variable appearance at high-resolution chest CT. *Radiology* 2000; 217: 701–705.

46 Park JS, Lee KS, Kim JS, *et al.* Nonspecific interstitial pneumonia with fibrosis: radiographic and CT findings in seven patients. *Radiology* 1995; 195: 645–648.

47 Do KH, Lee JS, Colby TV, *et al.* Nonspecific interstitial pneumonia *versus* usual interstitial pneumonia: differences in the density histogram of high-resolution CT. *J Comput Assist Tomogr* 2005; 29: 544–548.

48 Elliot TL, Lynch DA, Newell JD Jr, *et al.* High-resolution computed tomography features of nonspecific interstitial pneumonia and usual interstitial pneumonia. *J Comput Assist Tomogr* 2005; 29: 339–345.

49 Kim TS, Lee KS, Chung MP, *et al.* Nonspecific interstitial pneumonia with fibrosis: high-resolution CT and pathologic findings. *AJR Am J Roentgenol* 1998; 171: 1645–1650.

50 Tominaga J, Iwasawa T, Murota M, *et al.* Computed tomography findings of current nonspecific interstitial pneumonia based on the 2013 updated classification of idiopathic interstitial pneumonias: what is a characteristic of previously diagnosed nonspecific interstitial pneumonia excluded from the updated classification. *Jpn J Radiol* 2021; 39: 47–55.

51 Ebner L, Christodoulidis S, Stathopoulou T, *et al.* Meta-analysis of the radiological and clinical features of usual interstitial pneumonia (UIP) and nonspecific interstitial pneumonia (NSIP). *PLoS One* 2020; 15: e0226084.

52 Sumikawa H, Johkoh T, Fujimoto K, *et al.* Pathologically proved nonspecific interstitial pneumonia: CT pattern analysis as compared with usual interstitial pneumonia CT pattern. *Radiology* 2014; 272: 549–556.

53 Kim MY, Song JW, Do KH, *et al.* Idiopathic nonspecific interstitial pneumonia: changes in high-resolution computed tomography on long-term follow-up. *J Comput Assist Tomogr* 2012; 36: 170–174.

54 Silva CI, Müller NL, Lynch DA, *et al.* Chronic hypersensitivity pneumonitis: differentiation from idiopathic pulmonary fibrosis and nonspecific interstitial pneumonia by using thin-section CT. *Radiology* 2008; 246: 288–297.

55 Screaton NJ, Hiorns MP, Lee KS, *et al.* Serial high resolution CT in non-specific interstitial pneumonia: prognostic value of the initial pattern. *Clin Radiol* 2005; 60: 96–104.

56 Enomoto N, Sumikawa H, Sugiura H, *et al.* Clinical, radiological, and pathological evaluation of “NSIP with OP overlap” pattern compared with NSIP in patients with idiopathic interstitial pneumonias. *Respir Med* 2020; 174: 106201.

57 Silva CI, Müller NL, Hansell DM, *et al.* Nonspecific interstitial pneumonia and idiopathic pulmonary fibrosis: changes in pattern and distribution of disease over time. *Radiology* 2008; 247: 251–259.

58 Craig PJ, Wells AU, Doffman S, *et al.* Desquamative interstitial pneumonia, respiratory bronchiolitis and their relationship to smoking. *Histopathology* 2004; 45: 275–282.

59 Fukuoka J, Franks TJ, Colby TV, *et al.* Peribronchiolar metaplasia: a common histologic lesion in diffuse lung disease and a rare cause of interstitial lung disease: clinicopathologic features of 15 cases. *Am J Surg Pathol* 2005; 29: 948–954.

60 Yousem SA, Dacic S. Idiopathic bronchiolocentric interstitial pneumonia. *Mod Pathol* 2002; 15: 1148–1153.

61 Churg A, Myers J, Suarez T, *et al.* Airway-centered interstitial fibrosis: a distinct form of aggressive diffuse lung disease. *Am J Surg Pathol* 2004; 28: 62–68.

62 Kuranishi LT, Leslie KO, Ferreira RG, *et al.* Airway-centered interstitial fibrosis: etiology, clinical findings and prognosis. *Respir Res* 2015; 16: 55.

Downloaded from https://publications.ersnet.org on October 19, 2026 by guest. Please see licensing information on first page for reuse rights.

63 Mark EJ, Ruangchira-urai R. Bronchiolitis interstitial pneumonitis: a pathologic study of 31 lung biopsies with features intermediate between bronchiolitis obliterans organizing pneumonia and usual interstitial pneumonitis, with clinical correlation. *Ann Diagn Pathol* 2008; 12: 171–180.

64 Gaxiola M, Buendia-Roldán I, Mejía M, *et al.* Morphologic diversity of chronic pigeon breeder's disease: clinical features and survival. *Respir Med* 2011; 105: 608–614.

65 Silbernagel E, Morresi-Hauf A, Reu S, *et al.* Airway-centered interstitial fibrosis – an under-recognized subtype of diffuse parenchymal lung diseases. *Sarcoidosis Vasc Diffuse Lung Dis* 2018; 35: 218–229.

66 Liebow AA, Carrington CB. The interstitial pneumonias. *In*: Simon M, Potchen EJ, LeMay M, eds. Frontiers of Pulmonary Radiology. Vol. 1. New York, Grune and Stratton, 1969; pp. 102–141.

67 Churg A, Muller NL, Flint J, *et al.* Chronic hypersensitivity pneumonitis. *Am J Surg Pathol* 2006; 30: 201–208.

68 Chiba S, Tsuchiya K, Akashi T, *et al.* Chronic hypersensitivity pneumonitis with a usual interstitial pneumonia-like pattern: correlation between histopathologic and clinical findings. *Chest* 2016; 149: 1473–1481.

69 Wright JL, Churg A, Hague CJ, *et al.* Pathologic separation of idiopathic pulmonary fibrosis from fibrotic hypersensitivity pneumonitis. *Mod Pathol* 2020; 33: 616–625.

70 Lynch DA, Newell JD, Logan PM, *et al.* Can CT distinguish hypersensitivity pneumonitis from idiopathic pulmonary fibrosis? *AJR Am J Roentgenol* 1995; 165: 807–811.

71 Salisbury ML, Gross BH, Chughtai A, *et al.* Development and validation of a radiological diagnosis model for hypersensitivity pneumonitis. *Eur Respir J* 2018; 52: 1800443.

72 Hansell DM, Moskovic E. High-resolution computed tomography in extrinsic allergic alveolitis. *Clin Radiol* 1991; 43: 8–12.

73 Hanak V, Kalra S, Aksamit TR, *et al.* Hot tub lung: presenting features and clinical course of 21 patients. *Respir Med* 2006; 100: 610–615.

74 Lacasse Y, Fraser RS, Fournier M, *et al.* Diagnostic accuracy of transbronchial biopsy in acute farmer's lung disease. *Chest* 1997; 112: 1459–1465.

75 Silver SF, Müller NL, Miller RR, *et al.* Hypersensitivity pneumonitis: evaluation with CT. *Radiology* 1989; 173: 441–445.

76 Ohtani Y, Saiki S, Kitaichi M, *et al.* Chronic bird fancier's lung: histopathological and clinical correlation. An application of the 2002 ATS/ERS consensus classification of the idiopathic interstitial pneumonias. *Thorax* 2005; 60: 665–671.

77 Churg A, Sin DD, Everett D, *et al.* Pathologic patterns and survival in chronic hypersensitivity pneumonitis. *Am J Surg Pathol* 2009; 33: 1765–1770.

78 Wang P, Jones KD, Urisman A, *et al.* Pathologic findings and prognosis in a large prospective cohort of chronic hypersensitivity pneumonitis. *Chest* 2017; 152: 502–509.

79 Akashi T, Takemura T, Ando N, *et al.* Histopathologic analysis of sixteen autopsy cases of chronic hypersensitivity pneumonitis and comparison with idiopathic pulmonary fibrosis/usual interstitial pneumonia. *Am J Clin Pathol* 2009; 131: 405–415.

80 Trahan S, Hanak V, Ryu JH, *et al.* Role of surgical lung biopsy in separating chronic hypersensitivity pneumonia from usual interstitial pneumonia/idiopathic pulmonary fibrosis: analysis of 31 biopsies from 15 patients. *Chest* 2008; 134: 126–132.

81 Castonguay MC, Ryu JH, Yi ES, *et al.* Granulomas and giant cells in hypersensitivity pneumonitis. *Hum Pathol* 2015; 46: 607–613.

82 Takemura T, Akashi T, Kamiya H, *et al.* Pathological differentiation of chronic hypersensitivity pneumonitis from idiopathic pulmonary fibrosis/usual interstitial pneumonia. *Histopathology* 2012; 61: 1026–1035.

83 Tanizawa K, Ley B, Vittinghoff E, *et al.* Significance of bronchiolocentric fibrosis in patients with histopathological usual interstitial pneumonia. *Histopathology* 2019; 74: 1088–1097.

84 Ochi J, Ohtani Y, Takemura T, *et al.* Histological variability and consequences in chronic bird-related hypersensitivity pneumonitis. *Respirology* 2017; 22: 1350–1356.

85 Mukhopadhyay S, Katzenstein AL. Pulmonary disease due to aspiration of food and other particulate matter: a clinicopathologic study of 59 cases diagnosed on biopsy or resection specimens. *Am J Surg Pathol* 2007; 31: 752–759.

86 García-Manso IG, Arenas-Jiménez J, García-Sevila R, *et al.* Mosaic attenuation in non-fibrotic areas as a predictor of non-usual interstitial pneumonia pathologic diagnosis. *Sci Rep* 2022; 12: 7289.

87 Petnak T, Moua T. Exposure assessment in hypersensitivity pneumonitis: a comprehensive review and proposed screening questionnaire. *ERJ Open Res* 2020; 6: 00230-2020.

88 Barnes H, Morisset J, Molyneaux P, *et al.* A systematically derived exposure assessment instrument for chronic hypersensitivity pneumonitis. *Chest* 2020; 157: 1506–1512.

89 Singh S, Collins BF, Sharma BB, *et al.* Interstitial lung disease in India. Results of a prospective registry. *Am J Respir Crit Care Med* 2017; 195: 801–813.

90 Kang D, Nakayama T, Togashi M, *et al.* Two forms of diffuse alveolar damage in the lungs of patients with acute respiratory distress syndrome. *Hum Pathol* 2009; 40: 1618–1627.

Downloaded from https://publications.ersnet.org on October 19, 2026 by guest. Please see licensing information on first page for reuse rights.

91 Araya J, Kawabata Y, Jinho P, *et al.* Clinically occult subpleural fibrosis and acute interstitial pneumonia a precursor to idiopathic pulmonary fibrosis? *Respirology* 2008; 13: 408–412.
92 Vourlekis JS, Brown KK, Cool CD, *et al.* Acute interstitial pneumonitis. Case series and review of the literature. *Medicine* 2000; 79: 369–378.
93 Parambil JG, Myers JL, Aubry MC, *et al.* Causes and prognosis of diffuse alveolar damage diagnosed on surgical lung biopsy. *Chest* 2007; 132: 50–57.
94 Thille AW, Esteban A, Fernández-Segoviano P, *et al.* Chronology of histological lesions in acute respiratory distress syndrome with diffuse alveolar damage: a prospective cohort study of clinical autopsies. *Lancet Respir Med* 2013; 1: 395–401.
95 Ichikado K, Johkoh T, Ikezoe J, *et al.* Acute interstitial pneumonia: high-resolution CT findings correlated with pathology. *AJR Am J Roentgenol* 1997; 168: 333–338.
96 Mihara N, Johkoh T, Ichikado K, *et al.* Can acute interstitial pneumonia be differentiated from bronchiolitis obliterans organizing pneumonia by high-resolution CT? *Radiat Med* 2000; 18: 299–304.
97 Ichikado K, Suga M, Muranaka H, *et al.* Prediction of prognosis for acute respiratory distress syndrome with thin-section CT: validation in 44 cases. *Radiology* 2006; 238: 321–329.
98 Desai SR, Wells AU, Rubens MB, *et al.* Acute respiratory distress syndrome: CT abnormalities at long-term follow-up. *Radiology* 1999; 210: 29–35.
99 Primack SL, Hartman TE, Ikezoe J, *et al.* Acute interstitial pneumonia: radiographic and CT findings in nine patients. *Radiology* 1993; 188: 817–820.
100 Tomiyama N, Müller NL, Johkoh T, *et al.* Acute respiratory distress syndrome and acute interstitial pneumonia: comparison of thin-section CT findings. *J Comput Assist Tomogr* 2001; 25: 28–33.
101 Johkoh T, Müller NL, Taniguchi H, *et al.* Acute interstitial pneumonia: thin-section CT findings in 36 patients. *Radiology* 1999; 211: 859–863.
102 Ichikado K, Suga M, Müller NL, *et al.* Acute interstitial pneumonia: comparison of high-resolution computed tomography findings between survivors and nonsurvivors. *Am J Respir Crit Care Med* 2002; 165: 1551–1556.
103 Huang CY, Wu PW, Wong YC, *et al.* Effects of high-resolution CT changes on prognosis predictability in acute respiratory distress syndrome with diffuse alveolar damage. *J Clin Med* 2022; 11: 2458.
104 Collard HR, Ryerson CJ, Corte TJ, *et al.* Acute exacerbation of idiopathic pulmonary fibrosis. An international working group report. *Am J Respir Crit Care Med* 2016; 194: 265–275.
105 Hutchinson JP, Fogarty AW, McKeever TM, *et al.* In-hospital mortality after surgical lung biopsy for interstitial lung disease in the United States. 2000 to 2011. *Am J Respir Crit Care Med* 2016; 193: 1161–1167.
106 Zhou G, Feng Y, Wang S, *et al.* Transbronchial lung cryobiopsy may be of value for nonresolving acute respiratory distress syndrome: case series and systematic literature review. *BMC Pulm Med* 2020; 20: 183.
107 Eisenmann S, Lambrecht N, Diessel L, *et al.* Transbronchial cryobiopsy in unexplained, severe ARDS: a single center retrospective case series. *BMC Pulm Med* 2023; 23: 5.
108 Frankel SK, Cool CD, Lynch DA, *et al.* Idiopathic pleuroparenchymal fibroelastosis: description of a novel clinicopathologic entity. *Chest* 2004; 126: 2007–2013.
109 Amitani R, Niimi A, Kuse F. Idiopathic pulmonary upper lobe fibrosis (IPUF). *Kokyu* 1992; 11: 693–699.
110 Fujisawa T, Mori K, Mikamo M, *et al.* Nationwide cloud-based integrated database of idiopathic interstitial pneumonias for multidisciplinary discussion. *Eur Respir J* 2019; 53: 1802243.
111 Tanizawa K, Handa T, Kubo T, *et al.* Clinical significance of radiological pleuroparenchymal fibroelastosis pattern in interstitial lung disease patients registered for lung transplantation: a retrospective cohort study. *Respir Res* 2018; 19: 162.
112 Nakatani T, Arai T, Kitaichi M, *et al.* Pleuroparenchymal fibroelastosis from a consecutive database: a rare disease entity? *Eur Respir J* 2015; 45: 1183–1186.
113 Oda T, Ogura T, Kitamura H, *et al.* Distinct characteristics of pleuroparenchymal fibroelastosis with usual interstitial pneumonia compared with idiopathic pulmonary fibrosis. *Chest* 2014; 146: 1248–1255.
114 Lee SI, Chae EJ, Song JS, *et al.* Pleuroparenchymal fibroelastosis in patients with idiopathic pulmonary fibrosis. *Respirology* 2020; 25: 1046–1052.
115 Ishii H, Watanabe K, Kushima H, *et al.* Pleuroparenchymal fibroelastosis diagnosed by multidisciplinary discussions in Japan. *Respir Med* 2018; 141: 190–197.
116 Reddy TL, Tominaga M, Hansell DM, *et al.* Pleuroparenchymal fibroelastosis: a spectrum of histopathological and imaging phenotypes. *Eur Respir J* 2012; 40: 377–385.
117 Enomoto Y, Nakamura Y, Satake Y, *et al.* Clinical diagnosis of idiopathic pleuroparenchymal fibroelastosis: a retrospective multicenter study. *Respir Med* 2017; 133: 1–5.
118 Gentili F, Di Martino V, Forestieri M, *et al.* Pleuroparenchymal fibroelastosis-like lesions in clinical practice: a rare entity? Review of a radiological database. *Diagnostics* 2023; 13: 1627.
119 Khiroya R, Macaluso C, Montero MA, *et al.* Pleuroparenchymal fibroelastosis: a review of histopathologic features and the relationship between histologic parameters and survival. *Am J Surg Pathol* 2017; 41: 1683–1689.

Downloaded from https://publications.ersnet.org on October 19, 2026 by guest. Please see licensing information on first page for reuse rights.

120 Ikegami N, Nakajima N, Yoshizawa A, *et al.* Clinical, radiological and pathological features of idiopathic and secondary interstitial pneumonia with pleuroparenchymal fibroelastosis in patients undergoing lung transplantation. *Histopathology* 2022; 80: 665–676.

121 Rosenbaum JN, Butt YM, Johnson KA, *et al.* Pleuroparenchymal fibroelastosis: a pattern of chronic lung injury. *Hum Pathol* 2015; 46: 137–146.

122 von der Thüsen JH, Hansell DM, Tominaga M, *et al.* Pleuroparenchymal fibroelastosis in patients with pulmonary disease secondary to bone marrow transplantation. *Mod Pathol* 2011; 24: 1633–1639.

123 Takeuchi Y, Miyagawa-Hayashino A, Chen F, *et al.* Pleuroparenchymal fibroelastosis and non-specific interstitial pneumonia: frequent pulmonary sequelae of haematopoietic stem cell transplantation. *Histopathology* 2015; 66: 536–544.

124 Fujisawa T, Horiike Y, Egashira R, *et al.* Radiological pleuroparenchymal fibroelastosis-like lesion in idiopathic interstitial pneumonias. *Respir Res* 2021; 22: 290.

125 Kinoshita Y, Watanabe K, Ishii H, *et al.* Proliferation of elastic fibres in idiopathic pulmonary fibrosis: a whole-slide image analysis and comparison with pleuroparenchymal fibroelastosis. *Histopathology* 2017; 71: 934–942.

126 Kusagaya H, Nakamura Y, Kono M, *et al.* Idiopathic pleuroparenchymal fibroelastosis: consideration of a clinicopathological entity in a series of Japanese patients. *BMC Pulm Med* 2012; 12: 72.

127 Enomoto N, Kusagaya H, Oyama Y, *et al.* Quantitative analysis of lung elastic fibers in idiopathic pleuroparenchymal fibroelastosis (IPPFE): comparison of clinical, radiological, and pathological findings with those of idiopathic pulmonary fibrosis (IPF). *BMC Pulm Med* 2014; 14: 91.

128 Montero MA, Osadolor T, Khiroya R, *et al.* Restrictive allograft syndrome and idiopathic pleuroparenchymal fibroelastosis: do they really have the same histology? *Histopathology* 2017; 70: 1107–1113.

129 Cha YJ, Han J, Chung MP, *et al.* Pleuroparenchymal fibroelastosis in heterogeneous clinical conditions: clinicopathologic analysis of 7 cases. *Clin Respir J* 2018; 12: 1495–1502.

130 Piciucchi S, Tomassetti S, Casoni G, *et al.* High resolution CT and histological findings in idiopathic pleuroparenchymal fibroelastosis: features and differential diagnosis. *Respir Res* 2011; 12: 111.

131 Yoshida Y, Nagata N, Tsuruta N, *et al.* Heterogeneous clinical features in patients with pulmonary fibrosis showing histology of pleuroparenchymal fibroelastosis. *Respir Investig* 2016; 54: 162–169.

132 Kono M, Fujita Y, Takeda K, *et al.* Clinical significance of lower-lobe interstitial lung disease on high-resolution computed tomography in patients with idiopathic pleuroparenchymal fibroelastosis. *Respir Med* 2019; 154: 122–126.

133 Namba M, Masuda T, Takao S, *et al.* Extent of pulmonary fibrosis on high-resolution computed tomography is a prognostic factor in patients with pleuroparenchymal fibroelastosis. *Respir Investig* 2020; 58: 465–472.

134 Suzuki Y, Fujisawa T, Sumikawa H, *et al.* Disease course and prognosis of pleuroparenchymal fibroelastosis compared with idiopathic pulmonary fibrosis. *Respir Med* 2020; 171: 106078.

135 Egashira R, Yamaguchi K, Kondo T, *et al.* Pleuroparenchymal fibroelastosis (PPFE)-like finding on CT in daily practice – prevalence and serial changes. *Eur J Radiol Open* 2020; 7: 100296.

136 Sumikawa H, Johkoh T, Egashira R, *et al.* Pleuroparenchymal fibroelastosis-like lesions in patients with interstitial pneumonia diagnosed by multidisciplinary discussion with surgical lung biopsy. *Eur J Radiol Open* 2020; 7: 100298.

137 Koss MN, Hochholzer L, Langloss JM, *et al.* Lymphoid interstitial pneumonia: clinicopathological and immunopathological findings in 18 cases. *Pathology* 1987; 19: 178–185.

138 Setoguchi Y, Takahashi S, Nukiwa T, *et al.* Detection of human T-cell lymphotropic virus type I-related antibodies in patients with lymphocytic interstitial pneumonia. *Am Rev Respir Dis* 1991; 144: 1361–1365.

139 Taouli B, Brauner MW, Mourey I, *et al.* Thin-section chest CT findings of primary Sjogren's syndrome: correlation with pulmonary function. *Eur Radiol* 2002; 12: 1504–1511.

140 Malamou-Mitsi V, Tsai MM, Gal AA, *et al.* Lymphoid interstitial pneumonia not associated with HIV infection: role of Epstein–Barr virus. *Mod Pathol* 1992; 5: 487–491.

141 Cha SI, Fessler MB, Cool CD, *et al.* Lymphoid interstitial pneumonia: clinical features, associations and prognosis. *Eur Respir J* 2006; 28: 364–369.

142 van Zyl-Smit RN, Naidoo J, Wainwright H, *et al.* HIV associated lymphocytic interstitial pneumonia: a clinical, histological and radiographic study from an HIV endemic resource-poor setting. *BMC Pulm Med* 2015; 15: 38.

143 Fraune C, Churg A, Yi ES, *et al.* Lymphoid interstitial pneumonia (LIP) revisited: a critical reappraisal of the histologic spectrum of "radiologic" and "pathologic" LIP in the context of diffuse benign lymphoid proliferations of the lung. *Am J Surg Pathol* 2023; 47: 281–295.

144 Louza GF, Nobre LF, Mançano AD, *et al.* Lymphocytic interstitial pneumonia: computed tomography findings in 36 patients. *Radiol Bras* 2020; 53: 287–292.

145 Ichikawa Y, Kinoshita M, Koga T, *et al.* Lung cyst formation in lymphocytic interstitial pneumonia: CT features. *J Comput Assist Tomogr* 1994; 18: 745–748.

Downloaded from https://publications.ersnet.org on October 19, 2026 by guest. Please see licensing information on first page for reuse rights.

146 Johkoh T, Müller NL, Pickford HA, *et al.* Lymphocytic interstitial pneumonia: thin-section CT findings in 22 patients. *Radiology* 1999; 212: 567–572.
147 Honda O, Johkoh T, Ichikado K, *et al.* Differential diagnosis of lymphocytic interstitial pneumonia and malignant lymphoma on high-resolution CT. *AJR Am J Roentgenol* 1999; 173: 71–74.
148 Johkoh T, Ichikado K, Akira M, *et al.* Lymphocytic interstitial pneumonia: follow-up CT findings in 14 patients. *J Thorac Imaging* 2000; 15: 162–167.
149 King TE Jr, Lee JS. Cryptogenic organizing pneumonia. *N Engl J Med* 2022; 386: 1058–1069.
150 Cherian SV, Patel D, Machnicki S, *et al.* Algorithmic approach to the diagnosis of organizing pneumonia: a correlation of clinical, radiologic, and pathologic features. *Chest* 2022; 162: 156–178.
151 Epler GR, Colby TV, McLoud TC, *et al.* Bronchiolitis obliterans organizing pneumonia. *N Engl J Med* 1985; 312: 152–158.
152 Drakopanagiotakis F, Paschalaki K, Abu-Hijleh M, *et al.* Cryptogenic and secondary organizing pneumonia: clinical presentation, radiographic findings, treatment response, and prognosis. *Chest* 2011; 139: 893–900.
153 Chang J, Han J, Kim DW, *et al.* Bronchiolitis obliterans organizing pneumonia: clinicopathologic review of a series of 45 Korean patients including rapidly progressive form. *J Korean Med Sci* 2002; 17: 179–186.
154 Cazzato S, Zompatori M, Baruzzi G, *et al.* Bronchiolitis obliterans-organizing pneumonia: an Italian experience. *Respir Med* 2000; 94: 702–708.
155 Izumi T, Kitaichi M, Nishimura K, *et al.* Bronchiolitis obliterans organizing pneumonia. Clinical features and differential diagnosis. *Chest* 1992; 102: 715–719.
156 Oymak FS, Demirbas HM, Mavili E, *et al.* Bronchiolitis obliterans organizing pneumonia. Clinical and roentgenological features in 26 cases. *Respiration* 2005; 72: 254–262.
157 Lohr RH, Boland BJ, Douglas WW, *et al.* Organizing pneumonia. Features and prognosis of cryptogenic, secondary, and focal variants. *Arch Intern Med* 1997; 157: 1323–1329.
158 Lazor R, Vandevenne A, Pelletier A, *et al.* Cryptogenic organizing pneumonia. Characteristics of relapses in a series of 48 patients. The Groupe d'Etudes et de Recherche sur les Maladles "Orphelines" Pulmonaires (GERM"O"P). *Am J Respir Crit Care Med* 2000; 162: 571–577.
159 Basarakodu KR, Aronow WS, Nair CK, *et al.* Differences in treatment and in outcomes between idiopathic and secondary forms of organizing pneumonia. *Am J Ther* 2007; 14: 422–426.
160 Shimoda M, Tanaka Y, Morimoto K, *et al.* Spontaneous resolution of cryptogenic organizing pneumonia: observational study. *Medicine* 2023; 102: e34277.
161 Yoo JW, Song JW, Jang SJ, *et al.* Comparison between cryptogenic organizing pneumonia and connective tissue disease-related organizing pneumonia. *Rheumatology* 2011; 50: 932–938.
162 Cendon L, Rafecas Codern A, de la Rosa D, *et al.* Systematic review of systemic corticosteroids for treatment of organizing pneumonia. *Open Respir Arch* 2022; 4: 100211.
163 Myall KJ, Mukherjee B, Castanheira AM, *et al.* Persistent post-COVID-19 interstitial lung disease. An observational study of corticosteroid treatment. *Ann Am Thorac Soc* 2021; 18: 799–806.
164 Cordier JF, Loire R, Brune J. Idiopathic bronchiolitis obliterans organizing pneumonia. Definition of characteristic clinical profiles in a series of 16 patients. *Chest* 1989; 96: 999–1004.
165 Guerry-Force ML, Müller NL, Wright JL, *et al.* A comparison of bronchiolitis obliterans with organizing pneumonia, usual interstitial pneumonia, and small airways disease. *Am Rev Respir Dis* 1987; 135: 705–712.
166 Yousem SA. Cicatricial variant of cryptogenic organizing pneumonia. *Hum Pathol* 2017; 64: 76–82.
167 Churg A, Wright JL, Bilawich A. Cicatricial organising pneumonia mimicking a fibrosing interstitial pneumonia. *Histopathology* 2018; 72: 846–854.
168 Müller NL, Staples CA, Miller RR. Bronchiolitis obliterans organizing pneumonia: CT features in 14 patients. *AJR Am J Roentgenol* 1990; 154: 983–987.
169 Gomes R, Padrão E, Dabó H, *et al.* Acute fibrinous and organizing pneumonia: a report of 13 cases in a tertiary university hospital. *Medicine* 2016; 95: e4073.
170 Ussavarungsi K, Kern RM, Roden AC, *et al.* Transbronchial cryobiopsy in diffuse parenchymal lung disease: retrospective analysis of 74 cases. *Chest* 2017; 151: 400–408.
171 Sen T, Udwadia ZF. Cryptogenic organizing pneumonia: clinical profile in a series of 34 admitted patients in a hospital in India. *J Assoc Physicians India* 2008; 56: 229–232.
172 Poletti V, Cazzato S, Minicuci N, *et al.* The diagnostic value of bronchoalveolar lavage and transbronchial lung biopsy in cryptogenic organizing pneumonia. *Eur Respir J* 1996; 9: 2513–2516.
173 Jara-Palomares L, Gomez-Izquierdo L, Gonzalez-Vergara D, *et al.* Utility of high-resolution computed tomography and BAL in cryptogenic organizing pneumonia. *Respir Med* 2010; 104: 1706–1711.
174 Ravaglia C, Wells AU, Tomassetti S, *et al.* Diagnostic yield and risk/benefit analysis of trans-bronchial lung cryobiopsy in diffuse parenchymal lung diseases: a large cohort of 699 patients. *BMC Pulm Med* 2019; 19: 16.
175 Korevaar DA, Colella S, Fally M, *et al.* European Respiratory Society guidelines on transbronchial lung cryobiopsy in the diagnosis of interstitial lung diseases. *Eur Respir J* 2022; 60: 2200425.
176 Ghiani A, Neurohr C. Diagnostic yield, safety, and impact of transbronchial lung biopsy in mechanically ventilated, critically ill patients: a retrospective study. *BMC Pulm Med* 2021; 21: 15.

Downloaded from https://publications.ersnet.org on October 19, 2026 by guest. Please see licensing information on first page for reuse rights.

177 Majori M, Poletti V, Curti A, *et al.* Bronchoalveolar lavage in bronchiolitis obliterans organizing pneumonia primed by radiation therapy to the breast. *J Allergy Clin Immunol* 2000; 105: 239–244.

178 Meyer KC, Raghu G, Baughman RP, *et al.* An official American Thoracic Society clinical practice guideline: the clinical utility of bronchoalveolar lavage cellular analysis in interstitial lung disease. *Am J Respir Crit Care Med* 2012; 185: 1004–1014.

179 Choi KJ, Yoo EH, Kim KC, *et al.* Comparison of clinical features and prognosis in patients with cryptogenic and secondary organizing pneumonia. *BMC Pulm Med* 2021; 21: 336.

180 Costabel U, Teschler H, Guzman J. Bronchiolitis obliterans organizing pneumonia (BOOP): the cytological and immunocytological profile of bronchoalveolar lavage. *Eur Respir J* 1992; 5: 791–797.

181 Capelozzi VL, Faludi EP, Balthazar AB, *et al.* Bronchoalveolar lavage improves diagnostic accuracy in patients with diffuse lung disease. *Diagn Cytopathol* 2013; 41: 1–8.

182 Domagala-Kulawik J, Skirecki T, Maskey-Warzechowska M, *et al.* Bronchoalveolar lavage total cell count in interstitial lung diseases – does it matter? *Inflammation* 2012; 35: 803–809.

183 Espoladore LM, Gregório BB, Lima MS, *et al.* Cytological analysis of bronchoalveolar lavage in patients with interstitial lung diseases and the relation of cytological analysis to fibrosis in high-resolution computed tomography. *Anal Quant Cytopathol Histpathol* 2014; 36: 206–212.

184 Ito A, Ishida T, Tachibana H, *et al.* Utility of procalcitonin for differentiating cryptogenic organising pneumonia from community-acquired pneumonia. *Clin Chem Lab Med* 2019; 57: 1632–1637.

185 Bergantini L, d'Alessandro M, Cameli P, *et al.* Integrated approach to bronchoalveolar lavage cytology to distinguish interstitial lung diseases. *Eur J Intern Med* 2021; 89: 76–80.

186 Baha A, Yildirim F, Köktürk N, *et al.* Cryptogenic and secondary organizing pneumonia: clinical presentation, radiological and laboratory findings, treatment, and prognosis in 56 cases. *Turk Thorac J* 2018; 19: 201–208.

187 Kim SJ, Lee KS, Ryu YH, *et al.* Reversed halo sign on high-resolution CT of cryptogenic organizing pneumonia: diagnostic implications. *AJR Am J Roentgenol* 2003; 180: 1251–1254.

188 Ujita M, Renzoni EA, Veeraraghavan S, *et al.* Organizing pneumonia: perilobular pattern at thin-section CT. *Radiology* 2004; 232: 757–761.

189 Lee KS, Kullnig P, Hartman TE, *et al.* Cryptogenic organizing pneumonia: CT findings in 43 patients. *AJR Am J Roentgenol* 1994; 162: 543–546.

190 Lee JW, Lee KS, Lee HY, *et al.* Cryptogenic organizing pneumonia: serial high-resolution CT findings in 22 patients. *AJR Am J Roentgenol* 2010; 195: 916–922.

191 Okada F, Ando Y, Honda K, *et al.* Comparison of pulmonary CT findings and serum KL-6 levels in patients with cryptogenic organizing pneumonia. *Br J Radiol* 2009; 82: 212–218.

192 Huo Z, Feng R, Tian X, *et al.* Clinicopathological findings of focal organizing pneumonia: a retrospective study of 37 cases. *Int J Clin Exp Pathol* 2015; 8: 511–516.

193 Garrana SH, Som A, Ndakwah GS, *et al.* Comparison of chest CT findings of COVID-19, influenza, and organizing pneumonia: a multireader study. *AJR Am J Roentgenol* 2021; 217: 1093–1102.

194 Dai JH, Li H, Shen W, *et al.* Clinical and radiological profile of acute fibrinous and organizing pneumonia: a retrospective study. *Chin Med J* 2015; 128: 2701–2706.

195 Onishi Y, Kawamura T, Higashino T, *et al.* Clinical features of acute fibrinous and organizing pneumonia: an early histologic pattern of various acute inflammatory lung diseases. *PLoS One* 2021; 16: e0249300.

196 Kim MC, Kim YW, Kwon BS, *et al.* Clinical features and long-term prognosis of acute fibrinous and organizing pneumonia histologically confirmed by surgical lung biopsy. *BMC Pulm Med* 2022; 22: 56.

197 Beasley MB, Franks TJ, Galvin JR, *et al.* Acute fibrinous and organizing pneumonia: a histological pattern of lung injury and possible variant of diffuse alveolar damage. *Arch Pathol Lab Med* 2002; 126: 1064–1070.

198 Feinstein MB, DeSouza SA, Moreira AL, *et al.* A comparison of the pathological, clinical and radiographical, features of cryptogenic organising pneumonia, acute fibrinous and organising pneumonia and granulomatous organising pneumonia. *J Clin Pathol* 2015; 68: 441–447.

199 Lee JH, Yum HK, Jamous F, *et al.* Diagnostic procedures and clinico-radiological findings of acute fibrinous and organizing pneumonia: a systematic review and pooled analysis. *Eur Radiol* 2021; 31: 7283–7294.

200 Zaizen Y, Tabata K, Yamano Y, *et al.* Cicatricial organising pneumonia associated with fibrosing interstitial pneumonia – a clinicopathological study. *Histopathology* 2022; 80: 279–290.

201 Woge MJ, Ryu JH, Bartholmai BJ, *et al.* Cicatricial organizing pneumonia: a clinicopathologic and radiologic study on a cohort diagnosed by surgical lung biopsy at a single institution. *Hum Pathol* 2020; 101: 58–63.

202 Scheidl SJ, Kusej M, Flick H, *et al.* Clinical manifestations of respiratory bronchiolitis as an incidental finding in surgical lung biopsies: a retrospective analysis of a large Austrian registry. *Respiration* 2016; 91: 26–33.

203 Fraig M, Shreesha U, Savici D, *et al.* Respiratory bronchiolitis: a clinicopathologic study in current smokers, ex-smokers, and never-smokers. *Am J Surg Pathol* 2002; 26: 647–653.

204 Kawabata Y, Hoshi E, Murai K, *et al.* Smoking-related changes in the background lung of specimens resected for lung cancer: a semiquantitative study with correlation to postoperative course. *Histopathology* 2008; 53: 707–714.

205 Yousem SA. Respiratory bronchiolitis-associated interstitial lung disease with fibrosis is a lesion distinct from fibrotic nonspecific interstitial pneumonia: a proposal. *Mod Pathol* 2006; 19: 1474–1479.

Downloaded from https://publications.ersnet.org on October 19, 2026 by guest. Please see licensing information on first page for reuse rights.

206 Reddy TL, Mayo J, Churg A. Respiratory bronchiolitis with fibrosis. High-resolution computed tomography findings and correlation with pathology. *Ann Am Thorac Soc* 2013; 10: 590–601.

207 Katzenstein AL, Mukhopadhyay S, Zanardi C, *et al.* Clinically occult interstitial fibrosis in smokers: classification and significance of a surprisingly common finding in lobectomy specimens. *Hum Pathol* 2010; 41: 316–325.

208 Fabre A, Treacy A, Lavelle LP, *et al.* Smoking-related interstitial fibrosis: evidence of radiologic regression with advancing age and smoking cessation. *COPD* 2017; 14: 603–609.

209 Chae KJ, Jin GY, Jung HN, *et al.* Differentiating smoking-related interstitial fibrosis (SRIF) from usual interstitial pneumonia (UIP) with emphysema using CT features based on pathologically proven cases. *PLoS One* 2016; 11: e0162231.

210 Raoof S, Shah M, Make B, *et al.* Lung imaging in COPD part 1: clinical usefulness. *Chest* 2023; 164: 69–84.

211 Otani H, Tanaka T, Murata K, *et al.* Smoking-related interstitial fibrosis combined with pulmonary emphysema: computed tomography-pathologic correlative study using lobectomy specimens. *Int J Chron Obstruct Pulmon Dis* 2016; 11: 1521–1532.

212 Watanabe Y, Kawabata Y, Kanauchi T, *et al.* Multiple, thin-walled cysts are one of the HRCT features of airspace enlargement with fibrosis. *Eur J Radiol* 2015; 84: 986–992.

213 Hellemons ME, Moor CC, von der Thüsen J, *et al.* Desquamative interstitial pneumonia: a systematic review of its features and outcomes. *Eur Respir Rev* 2020; 29: 190181.

214 Zhao JG, Zhou GW, Zhao L, *et al.* Safety and accuracy of transbronchial lung cryobiopsy in diagnosing desquamative interstitial pneumonia. *Clin Respir J* 2022; 16: 309–316.

215 Barata M, Caetano Mota P, Melo N, *et al.* Transbronchial lung cryobiopsy in smoking-related interstitial lung diseases. *Sarcoidosis Vasc Diffuse Lung Dis* 2020; 37: e2020013.

216 Kawabata Y, Takemura T, Hebisawa A, *et al.* Eosinophilia in bronchoalveolar lavage fluid and architectural destruction are features of desquamative interstitial pneumonia. *Histopathology* 2008; 52: 194–202.

217 Akira M, Yamamoto S, Hara H, *et al.* Serial computed tomographic evaluation in desquamative interstitial pneumonia. *Thorax* 1997; 52: 333–337.

218 Park JS, Brown KK, Tuder RM, *et al.* Respiratory bronchiolitis-associated interstitial lung disease: radiologic features with clinical and pathologic correlation. *J Comput Assist Tomogr* 2002; 26: 13–20.

219 Yousem SA, Colby TV, Gaensler EA. Respiratory bronchiolitis-associated interstitial lung disease and its relationship to desquamative interstitial pneumonia. *Mayo Clin Proc* 1989; 64: 1373–1380.

220 Doan ML, Guillerman RP, Dishop MK, *et al.* Clinical, radiological and pathological features of ABCA3 mutations in children. *Thorax* 2008; 63: 366–373.

221 Li Y, Seidl E, Knoflach K, *et al.* ABCA3-related interstitial lung disease beyond infancy. *Thorax* 2023; 78: 587–595.

222 Staats P, Kligerman S, Todd N, *et al.* A comparative study of honeycombing on high resolution computed tomography with histologic lung remodeling in explants with usual interstitial pneumonia. *Pathol Res Pract* 2015; 211: 55–61.

223 Vassallo R, Jensen EA, Colby TV, *et al.* The overlap between respiratory bronchiolitis and desquamative interstitial pneumonia in pulmonary Langerhans cell histiocytosis: high-resolution CT, histologic, and functional correlations. *Chest* 2003; 124: 1199–1205.

224 Kawabata Y, Takemura T, Hebisawa A, *et al.* Desquamative interstitial pneumonia may progress to lung fibrosis as characterized radiologically. *Respirology* 2012; 17: 1214–1221.

225 Ryu JH, Myers JL, Capizzi SA, *et al.* Desquamative interstitial pneumonia and respiratory bronchiolitis-associated interstitial lung disease. *Chest* 2005; 127: 178–184.

226 Hartman TE, Primack SL, Swensen SJ, *et al.* Desquamative interstitial pneumonia: thin-section CT findings in 22 patients. *Radiology* 1993; 187: 787–790.

227 Heyneman LE, Ward S, Lynch DA, *et al.* Respiratory bronchiolitis, respiratory bronchiolitis-associated interstitial lung disease, and desquamative interstitial pneumonia: different entities or part of the spectrum of the same disease process? *AJR Am J Roentgenol* 1999; 173: 1617–1622.

228 Hartman TE, Primack SL, Kang EY, *et al.* Disease progression in usual interstitial pneumonia compared with desquamative interstitial pneumonia. Assessment with serial CT. *Chest* 1996; 110: 378–382.

229 Singh J, Jaffe A, Schultz A, *et al.* Surfactant protein disorders in childhood interstitial lung disease. *Eur J Pediatr* 2021; 180: 2711–2721.

230 Cottin V. Desquamative interstitial pneumonia: still orphan and not always benign. *Eur Respir Rev* 2020; 29: 200183.

231 De Giacomi F, Vassallo R, Yi ES, *et al.* Acute eosinophilic pneumonia. Causes, diagnosis, and management. *Am J Respir Crit Care Med* 2018; 197: 728–736.

232 Chaaban T. Acute eosinophilic pneumonia associated with non-cigarette smoking products: a systematic review. *Adv Respir Med* 2020; 88: 142–146.

233 Uchiyama H, Suda T, Nakamura Y, *et al.* Alterations in smoking habits are associated with acute eosinophilic pneumonia. *Chest* 2008; 133: 1174–1180.

Downloaded from https://publications.ersnet.org on October 19, 2026 by guest. Please see licensing information on first page for reuse rights.

234 Allen JN, Pacht ER, Gadek JE, *et al.* Acute eosinophilic pneumonia as a reversible cause of noninfectious respiratory failure. *N Engl J Med* 1989; 321: 569–574.

235 Philit F, Etienne-Mastroïanni B, Parrot A, *et al.* Idiopathic acute eosinophilic pneumonia: a study of 22 patients. *Am J Respir Crit Care Med* 2002; 166: 1235–1239.

236 Di Lorenzo A, Rindi LV, Campogiani L, *et al.* Daptomycin-induced eosinophilic pneumonia: a case report and systematic review. *Chemotherapy* 2024; 69: 85–99.

237 Marchand E, Reynaud-Gaubert M, Lauque D, *et al.* Idiopathic chronic eosinophilic pneumonia. A clinical and follow-up study of 62 cases. The Groupe d'Etudes et de Recherche sur les Maladies "Orphelines" Pulmonaires (GERM"O"P). *Medicine* 1998; 77: 299–312.

238 Jederlinic PJ, Sicilian L, Gaensler EA. Chronic eosinophilic pneumonia. A report of 19 cases and a review of the literature. *Medicine* 1988; 67: 154–162.

239 Furuiye M, Yoshimura N, Kobayashi A, *et al.* Churg–Strauss syndrome *versus* chronic eosinophilic pneumonia on high-resolution computed tomographic findings. *J Comput Assist Tomogr* 2010; 34: 19–22.

240 Baqir M, Peikert T, Johnson TF, *et al.* Idiopathic chronic eosinophilic pneumonia evolving to pulmonary fibrosis: a retrospective analysis. *Sarcoidosis Vasc Diffuse Lung Dis* 2022; 39: e2022020.

241 Takeuchi N, Arai T, Sasaki Y, *et al.* Predictive factors for relapse in corticosteroid-treated patients with chronic eosinophilic pneumonia. *J Thorac Dis* 2022; 14: 4352–4360.

242 Mehrian P, Doroudinia A, Rashti A, *et al.* High-resolution computed tomography findings in chronic eosinophilic *vs*. cryptogenic organising pneumonia. *Int J Tuberc Lung Dis* 2017; 21: 1181–1186.

243 Durieu J, Wallaert B, Tonnel AB. Long-term follow-up of pulmonary function in chronic eosinophilic pneumonia. Groupe d'Etude en Pathologie Interstitielle de la Societe de Pathologie Thoracique du Nord. *Eur Respir J* 1997; 10: 286–291.

244 Marchand E, Etienne-Mastroianni B, Chanez P, *et al.* Idiopathic chronic eosinophilic pneumonia and asthma: how do they influence each other? *Eur Respir J* 2003; 22: 8–13.

245 Suzuki Y, Oyama Y, Hozumi H, *et al.* Persistent impairment on spirometry in chronic eosinophilic pneumonia: a longitudinal observation study (Shizuoka-CEP study). *Ann Allergy Asthma Immunol* 2017; 119: 422–428.

246 Tazelaar HD, Linz LJ, Colby TV, *et al.* Acute eosinophilic pneumonia: histopathologic findings in nine patients. *Am J Respir Crit Care Med* 1997; 155: 296–302.

247 Johkoh T, Müller NL, Akira M, *et al.* Eosinophilic lung diseases: diagnostic accuracy of thin-section CT in 111 patients. *Radiology* 2000; 216: 773–780.

248 Daimon T, Johkoh T, Sumikawa H, *et al.* Acute eosinophilic pneumonia: thin-section CT findings in 29 patients. *Eur J Radiol* 2008; 65: 462–467.

249 Cheon JE, Lee KS, Jung GS, *et al.* Acute eosinophilic pneumonia: radiographic and CT findings in six patients. *AJR Am J Roentgenol* 1996; 167: 1195–1199.

250 Arakawa H, Kurihara Y, Niimi H, *et al.* Bronchiolitis obliterans with organizing pneumonia *versus* chronic eosinophilic pneumonia: high-resolution CT findings in 81 patients. *AJR Am J Roentgenol* 2001; 176: 1053–1058.

251 Mayo JR, Müller NL, Road J, *et al.* Chronic eosinophilic pneumonia: CT findings in six cases. *AJR Am J Roentgenol* 1989; 153: 727–730.

252 Naughton M, Fahy J, FitzGerald MX. Chronic eosinophilic pneumonia. A long-term follow-up of 12 patients. *Chest* 1993; 103: 162–165.

253 Carrington CB, Addington WW, Goff AM, *et al.* Chronic eosinophilic pneumonia. *N Engl J Med* 1969; 280: 787–798.

254 Ebara H, Ikezoe J, Johkoh T, *et al.* Chronic eosinophilic pneumonia: evolution of chest radiograms and CT features. *J Comput Assist Tomogr* 1994; 18: 737–744.

255 Valent P, Klion AD, Horny HP, *et al.* Contemporary consensus proposal on criteria and classification of eosinophilic disorders and related syndromes. *J Allergy Clin Immunol* 2012; 130: 607–612.

256 Oyama Y, Fujisawa T, Hashimoto D, *et al.* Efficacy of short-term prednisolone treatment in patients with chronic eosinophilic pneumonia. *Eur Respir J* 2015; 45: 1624–1631.

257 Rhee CK, Min KH, Yim NY, *et al.* Clinical characteristics and corticosteroid treatment of acute eosinophilic pneumonia. *Eur Respir J* 2013; 41: 402–409.

258 Trapnell BC, Nakata K, Bonella F, *et al.* Pulmonary alveolar proteinosis. *Nat Rev Dis Primers* 2019; 5: 16.

259 McCarthy C, Carey BC, Trapnell BC. Autoimmune pulmonary alveolar proteinosis. *Am J Respir Crit Care Med* 2022; 205: 1016–1035.

260 Kumar A, Abdelmalak B, Inoue Y, *et al.* Pulmonary alveolar proteinosis in adults: pathophysiology and clinical approach. *Lancet Respir Med* 2018; 6: 554–565.

261 Salvaterra E, Campo I. Pulmonary alveolar proteinosis: from classification to therapy. *Breathe* 2020; 16: 200018.

262 Xu Z, Jing J, Wang H, *et al.* Pulmonary alveolar proteinosis in China: a systematic review of 241 cases. *Respirology* 2009; 14: 761–766.

Downloaded from https://publications.ersnet.org on October 19, 2026 by guest. Please see licensing information on first page for reuse rights.

263 Bonella F, Bauer PC, Griese M, *et al.* Pulmonary alveolar proteinosis: new insights from a single-center cohort of 70 patients. *Respir Med* 2011; 105: 1908–1916.
264 Campo I, Mariani F, Rodi G, *et al.* Assessment and management of pulmonary alveolar proteinosis in a reference center. *Orphanet J Rare Dis* 2013; 8: 40.
265 Inoue Y, Trapnell BC, Tazawa R, *et al.* Characteristics of a large cohort of patients with autoimmune pulmonary alveolar proteinosis in Japan. *Am J Respir Crit Care Med* 2008; 177: 752–762.
266 Byun MK, Kim DS, Kim YW, *et al.* Clinical features and outcomes of idiopathic pulmonary alveolar proteinosis in Korean population. *J Korean Med Sci* 2010; 25: 393–398.
267 Fijolek J, Wiatr E, Radzikowska E, *et al.* Pulmonary alveolar proteinosis during a 30-year observation. Diagnosis and treatment. *Pneumonol Alergol Pol* 2014; 82: 206–217.
268 Punatar AD, Kusne S, Blair JE, *et al.* Opportunistic infections in patients with pulmonary alveolar proteinosis. *J Infect* 2012; 65: 173–179.
269 Sakaue S, Yamaguchi E, Inoue Y, *et al.* Genetic determinants of risk in autoimmune pulmonary alveolar proteinosis. *Nat Commun* 2021; 12: 1032.
270 Griese M, Zarbock R, Costabel U, *et al.* GATA2 deficiency in children and adults with severe pulmonary alveolar proteinosis and hematologic disorders. *BMC Pulm Med* 2015; 15: 87.
271 Honma K, Chiyotani K. Pulmonary alveolar proteinosis as a component of massive fibrosis in cases of chronic pneumoconiosis. An autopsy study of 79 cases. *Zentralbl Pathol* 1991; 137: 414–417.
272 Tredano M, Griese M, Brasch F, *et al.* Mutation of SFTPC in infantile pulmonary alveolar proteinosis with or without fibrosing lung disease. *Am J Med Genet A* 2004; 126A: 18–26.
273 Hu-Wang E, Chelala L, Landeras L, *et al.* Pulmonary alveolar proteinosis-associated pulmonary fibrosis: evolutional changes and radiologic-pathologic correlation. *Radiol Cardiothorac Imaging* 2023; 5: e230040.
274 Akira M, Inoue Y, Arai T, *et al.* Pulmonary fibrosis on high-resolution CT of patients with pulmonary alveolar proteinosis. *AJR Am J Roentgenol* 2016; 207: 544–551.
275 Ishii H, Trapnell BC, Tazawa R, *et al.* Comparative study of high-resolution CT findings between autoimmune and secondary pulmonary alveolar proteinosis. *Chest* 2009; 136: 1348–1355.
276 Luo J, Yang D, Zhou S, *et al.* Crazy paving pattern caused by pulmonary alveolar proteinosis: CT findings and the pathologic basis. *Zhong Nan Da Xue Xue Bao Yi Xue Ban* 2014; 39: 924–929.
277 Choi HK, Park CM, Goo JM, *et al.* Pulmonary alveolar proteinosis *versus* exogenous lipoid pneumonia showing crazy-paving pattern: comparison of their clinical features and high-resolution CT findings. *Acta Radiol* 2010; 51: 407–412.
278 Holbert JM, Costello P, Li W, *et al.* CT features of pulmonary alveolar proteinosis. *AJR Am J Roentgenol* 2001; 176: 1287–1294.
279 Lee KN, Levin DL, Webb WR, *et al.* Pulmonary alveolar proteinosis: high-resolution CT, chest radiographic, and functional correlations. *Chest* 1997; 111: 989–995.
280 Godwin JD, Müller NL, Takasugi JE. Pulmonary alveolar proteinosis: CT findings. *Radiology* 1988; 169: 609–613.
281 Long Y, Liu G, Peng H, *et al.* Clinical characteristics of pulmonary alveolar proteinosis. *Zhong Nan Da Xue Xue Bao Yi Xue Ban* 2021; 46: 156–161.
282 Zhang D, Tian X, Feng R, *et al.* Secondary pulmonary alveolar proteinosis: a single-center retrospective study (a case series and literature review). *BMC Pulm Med* 2018; 18: 15.
283 Spagnolo P, Ryerson CJ, Guler S, *et al.* Occupational interstitial lung diseases. *J Intern Med* 2023; 294: 798–815.
284 Costabel U, Guzman J, Bonella F, *et al.* Bronchoalveolar lavage in other interstitial lung diseases. *Semin Respir Crit Care Med* 2007; 28: 514–524.
285 Mermolja M, Rott T, Debeljak A. Cytology of bronchoalveolar lavage in some rare pulmonary disorders: pulmonary alveolar proteinosis and amiodarone pulmonary toxicity. *Cytopathology* 1994; 5: 9–16.
286 Martin RJ, Coalson JJ, Rogers RM, *et al.* Pulmonary alveolar proteinosis: the diagnosis by segmental lavage. *Am Rev Respir Dis* 1980; 121: 819–825.
287 McCarthy C, Bonella F, O'Callaghan M, *et al.* European Respiratory Society guidelines for the diagnosis and management of pulmonary alveolar proteinosis. *Eur Respir J* 2024; 64: 2400725.
288 Azuma K, Takimoto T, Kasai T, *et al.* Diagnostic yield and safety of bronchofiberscopy for pulmonary alveolar proteinosis. *Respir Investig* 2021; 59: 757–765.
289 Samhouri BF, Tandon YK, Hartman TE, *et al.* Presenting clinicoradiologic features, causes, and clinical course of exogenous lipoid pneumonia in adults. *Chest* 2021; 160: 624–632.
290 Kim CH, Kim EJ, Lim JK, *et al.* Comparison of exogenous and endogenous lipoid pneumonia: the relevance to bronchial anthracofibrosis. *J Thorac Dis* 2018; 10: 2461–2466.
291 Gondouin A, Manzoni P, Ranfaing E, *et al.* Exogenous lipid pneumonia: a retrospective multicentre study of 44 cases in France. *Eur Respir J* 1996; 9: 1463–1469.
292 Lee KS, Müller NL, Hale V, *et al.* Lipoid pneumonia: CT findings. *J Comput Assist Tomogr* 1995; 19: 48–51.

Downloaded from https://publications.ersnet.org on October 19, 2026 by guest. Please see licensing information on first page for reuse rights.

293 Chiang IC, Lin YT, Liu GC, *et al.* Exogenous lipoid pneumonia: serial chest plain roentgenography and high-resolution computerized tomography findings. *Kaohsiung J Med Sci* 2003; 19: 593–598.

294 Marchiori E, Zanetti G, Mano CM, *et al.* Lipoid pneumonia in 53 patients after aspiration of mineral oil: comparison of high-resolution computed tomography findings in adults and children. *J Comput Assist Tomogr* 2010; 34: 9–12.

295 Laurent F, Philippe JC, Vergier B, *et al.* Exogenous lipoid pneumonia: HRCT, MR, and pathologic findings. *Eur Radiol* 1999; 9: 1190–1196.

296 Cozzi D, Bindi A, Cavigli E, *et al.* Exogenous lipoid pneumonia: when radiologist makes the difference. *Radiol Med* 2021; 126: 22–28.

297 Baron SE, Haramati LB, Rivera VT. Radiological and clinical findings in acute and chronic exogenous lipoid pneumonia. *J Thorac Imaging* 2003; 18: 217–224.

298 Lee JY, Lee KS, Kim TS, *et al.* Squalene-induced extrinsic lipoid pneumonia: serial radiologic findings in nine patients. *J Comput Assist Tomogr* 1999; 23: 730–735.

299 Nicholson AG, Florio R, Hansell DM, *et al.* Pulmonary involvement by Niemann–Pick disease. A report of six cases. *Histopathology* 2006; 48: 596–603.

300 Silverman JF, Turner RC, West RL, *et al.* Bronchoalveolar lavage in the diagnosis of lipoid pneumonia. *Diagn Cytopathol* 1989; 5: 3–8.

301 Lee JH, Chae EJ, Song JS, *et al.* Pleuroparenchymal fibroelastosis in Korean patients: clinico-radiologic-pathologic features and 2-year follow-up. *Korean J Intern Med* 2021; 36: Suppl. 1, S132–S141.

302 Enomoto Y, Nakamura Y, Colby TV, *et al.* Radiologic pleuroparenchymal fibroelastosis-like lesion in connective tissue disease-related interstitial lung disease. *PLoS One* 2017; 12: e0180283.

303 Gudmundsson E, Zhao A, Mogulkoc N, *et al.* Pleuroparenchymal fibroelastosis in idiopathic pulmonary fibrosis: survival analysis using visual and computer-based computed tomography assessment. *EClinicalMedicine* 2021; 38: 101009.

304 Gudmundsson E, Zhao A, Mogulkoc N, *et al.* Delineating associations of progressive pleuroparenchymal fibroelastosis in patients with pulmonary fibrosis. *ERJ Open Res* 2023; 9: 00637-2022.

305 Kato M, Sasaki S, Kurokawa K, *et al.* Usual interstitial pneumonia pattern in the lower lung lobes as a prognostic factor in idiopathic pleuroparenchymal fibroelastosis. *Respiration* 2019; 97: 319–328.

306 Oda T, Sekine A, Tabata E, *et al.* Comparison of clinical characteristics and outcomes between idiopathic and secondary pleuroparenchymal fibroelastosis. *J Clin Med* 2021; 10: 846.

307 Nakamura Y, Mori K, Enomoto Y, *et al.* Prognostic and clinical value of cluster analysis in idiopathic pleuroparenchymal fibroelastosis phenotypes. *J Clin Med* 2021; 10: 1498.

308 Kang J, Seo WJ, Lee EY, *et al.* Pleuroparenchymal fibroelastosis in rheumatoid arthritis-associated interstitial lung disease. *Respir Res* 2022; 23: 143.

309 Flaherty KR, Thwaite EL, Kazerooni EA, *et al.* Radiological *versus* histological diagnosis in UIP and NSIP: survival implications. *Thorax* 2003; 58: 143–148.

310 Bonifazi M, Sverzellati N, Negri E, *et al.* Pleuroparenchymal fibroelastosis in systemic sclerosis: prevalence and prognostic impact. *Eur Respir J* 2020; 56: 1902135.

311 Jacob J, Odink A, Brun AL, *et al.* Functional associations of pleuroparenchymal fibroelastosis and emphysema with hypersensitivity pneumonitis. *Respir Med* 2018; 138: 95–101.

312 Waseda Y, Johkoh T, Egashira R, *et al.* Antisynthetase syndrome: pulmonary computed tomography findings of adult patients with antibodies to aminoacyl-tRNA synthetases. *Eur J Radiol* 2016; 85: 1421–1426.

313 Debray MP, Borie R, Revel MP, *et al.* Interstitial lung disease in anti-synthetase syndrome: initial and follow-up CT findings. *Eur J Radiol* 2015; 84: 516–523.

314 Nurmi HM, Elfving PK, Kettunen HP, *et al.* Inflammatory myositis-associated interstitial lung disease can be distinguished from that associated with other connective tissue diseases. *J Thorac Dis* 2023; 15: 311–322.

315 Zuo Y, Ye L, Liu M, *et al.* Clinical significance of radiological patterns of HRCT and their association with macrophage activation in dermatomyositis. *Rheumatology* 2020; 59: 2829–2837.

316 Zamora AC, Hoskote SS, Abascal-Bolado B, *et al.* Clinical features and outcomes of interstitial lung disease in anti-Jo-1 positive antisynthetase syndrome. *Respir Med* 2016; 118: 39–45.

317 Chartrand S, Swigris JJ, Peykova L, *et al.* A multidisciplinary evaluation helps identify the antisynthetase syndrome in patients presenting as idiopathic interstitial pneumonia. *J Rheumatol* 2016; 43: 887–892.

318 Chen X, Jiang W, Jin Q, *et al.* Clinical, radiological and pathological features of anti-MDA5 antibody-associated interstitial lung disease. *RMD Open* 2023; 9: e003150.

319 Hwang JH, Misumi S, Sahin H, *et al.* Computed tomographic features of idiopathic fibrosing interstitial pneumonia: comparison with pulmonary fibrosis related to collagen vascular disease. *J Comput Assist Tomogr* 2009; 33: 410–415.

320 Cottin V, Selman M, Inoue Y, *et al.* Syndrome of combined pulmonary fibrosis and emphysema: an official ATS/ERS/JRS/ALAT research statement. *Am J Respir Crit Care Med* 2022; 206: e7–e41.

321 Guler SA, Ellison K, Algamdi M, *et al.* Heterogeneity in unclassifiable interstitial lung disease. A systematic review and meta-analysis. *Ann Am Thorac Soc* 2018; 15: 854–863.

Downloaded from https://publications.ersnet.org on October 19, 2026 by guest. Please see licensing information on first page for reuse rights.

322 Ryerson CJ, Urbania TH, Richeldi L, *et al.* Prevalence and prognosis of unclassifiable interstitial lung disease. *Eur Respir J* 2013; 42: 750–757.
323 Wang Y, Kuan PJ, Xing C, *et al.* Genetic defects in surfactant protein A2 are associated with pulmonary fibrosis and lung cancer. *Am J Hum Genet* 2009; 84: 52–59.
324 Thomas AQ, Lane K, Phillips J 3rd, *et al.* Heterozygosity for a surfactant protein C gene mutation associated with usual interstitial pneumonitis and cellular nonspecific interstitial pneumonitis in one kindred. *Am J Respir Crit Care Med* 2002; 165: 1322–1328.
325 Kannengiesser C, Borie R, Ménard C, *et al.* Heterozygous RTEL1 mutations are associated with familial pulmonary fibrosis. *Eur Respir J* 2015; 46: 474–485.
326 Stuart BD, Choi J, Zaidi S, *et al.* Exome sequencing links mutations in PARN and RTEL1 with familial pulmonary fibrosis and telomere shortening. *Nat Genet* 2015; 47: 512–517.
327 Cogan JD, Kropski JA, Zhao M, *et al.* Rare variants in RTEL1 are associated with familial interstitial pneumonia. *Am J Respir Crit Care Med* 2015; 191: 646–655.
328 Kropski JA, Reiss S, Markin C, *et al.* Rare genetic variants in PARN are associated with pulmonary fibrosis in families. *Am J Respir Crit Care Med* 2017; 196: 1481–1484.
329 Alder JK, Stanley SE, Wagner CL, *et al.* Exome sequencing identifies mutant TINF2 in a family with pulmonary fibrosis. *Chest* 2015; 147: 1361–1368.
330 Newton CA, Batra K, Torrealba J, *et al.* Telomere-related lung fibrosis is diagnostically heterogeneous but uniformly progressive. *Eur Respir J* 2016; 48: 1710–1720.
331 Newton CA, Oldham JM, Ley B, *et al.* Telomere length and genetic variant associations with interstitial lung disease progression and survival. *Eur Respir J* 2019; 53: 1801641.
332 Xue J, Gochuico BR, Alawad AS, *et al.* The HLA class II Allele DRB1*1501 is over-represented in patients with idiopathic pulmonary fibrosis. *PLoS One* 2011; 6: e14715.
333 Fingerlin TE, Zhang W, Yang IV, *et al.* Genome-wide imputation study identifies novel HLA locus for pulmonary fibrosis and potential role for auto-immunity in fibrotic idiopathic interstitial pneumonia. *BMC Genet* 2016; 17: 74.
334 Tsakiri KD, Cronkhite JT, Kuan PJ, *et al.* Adult-onset pulmonary fibrosis caused by mutations in telomerase. *Proc Natl Acad Sci USA* 2007; 104: 7552–7557.
335 Armanios MY, Chen JJ, Cogan JD, *et al.* Telomerase mutations in families with idiopathic pulmonary fibrosis. *N Engl J Med* 2007; 356: 1317–1326.
336 Sutton RM, Bittar HT, Sullivan DI, *et al.* Rare surfactant-related variants in familial and sporadic pulmonary fibrosis. *Hum Mutat* 2022; 43: 2091–2101.
337 Dressen A, Abbas AR, Cabanski C, *et al.* Analysis of protein-altering variants in telomerase genes and their association with MUC5B common variant status in patients with idiopathic pulmonary fibrosis: a candidate gene sequencing study. *Lancet Respir Med* 2018; 6: 603–614.
338 Petrovski S, Todd JL, Durheim MT, *et al.* An exome sequencing study to assess the role of rare genetic variation in pulmonary fibrosis. *Am J Respir Crit Care Med* 2017; 196: 82–93.
339 Zhang D, Newton CA, Wang B, *et al.* Utility of whole genome sequencing in assessing risk and clinically relevant outcomes for pulmonary fibrosis. *Eur Respir J* 2022; 60: 2200577.
340 Moll M, Peljto AL, Kim JS, *et al.* A polygenic risk score for idiopathic pulmonary fibrosis and interstitial lung abnormalities. *Am J Respir Crit Care Med* 2023; 208: 791–801.
341 Adegunsoye A, Kropski JA, Behr J, *et al.* Genetics and genomics of pulmonary fibrosis: charting the molecular landscape and shaping precision medicine. *Am J Respir Crit Care Med* 2024; 210: 401–423.
342 Seibold MA, Wise AL, Speer MC, *et al.* A common MUC5B promoter polymorphism and pulmonary fibrosis. *N Engl J Med* 2011; 364: 1503–1512.
343 Ley B, Newton CA, Arnould I, *et al.* The MUC5B promoter polymorphism and telomere length in patients with chronic hypersensitivity pneumonitis: an observational cohort-control study. *Lancet Respir Med* 2017; 5: 639–647.
344 Dhindsa RS, Mattsson J, Nag A, *et al.* Identification of a missense variant in SPDL1 associated with idiopathic pulmonary fibrosis. *Commun Biol* 2021; 4: 392.
345 Furusawa H, Peljto AL, Walts AD, *et al.* Common idiopathic pulmonary fibrosis risk variants are associated with hypersensitivity pneumonitis. *Thorax* 2022; 77: 508–510.
346 Mathai SK, Humphries S, Kropski JA, *et al. MUC5B* variant is associated with visually and quantitatively detected preclinical pulmonary fibrosis. *Thorax* 2019; 74: 1131–1139.
347 Noth I, Zhang Y, Ma SF, *et al.* Genetic variants associated with idiopathic pulmonary fibrosis susceptibility and mortality: a genome-wide association study. *Lancet Respir Med* 2013; 1: 309–317.
348 Juge PA, Lee JS, Ebstein E, *et al.* MUC5B promoter variant and rheumatoid arthritis with interstitial lung disease. *N Engl J Med* 2018; 379: 2209–2219.
349 Peljto AL, Selman M, Kim DS, *et al.* The MUC5B promoter polymorphism is associated with idiopathic pulmonary fibrosis in a Mexican cohort but is rare among Asian ancestries. *Chest* 2015; 147: 460–464.
350 Juge PA, Borie R, Kannengiesser C, *et al.* Shared genetic predisposition in rheumatoid arthritis-interstitial lung disease and familial pulmonary fibrosis. *Eur Respir J* 2017; 49: 1602314.

Downloaded from https://publications.ersnet.org on October 19, 2026 by guest. Please see licensing information on first page for reuse rights.

351 Ley B, Torgerson DG, Oldham JM, *et al.* Rare protein-altering telomere-related gene variants in patients with chronic hypersensitivity pneumonitis. *Am J Respir Crit Care Med* 2019; 200: 1154–1163.

352 Conti C, Montero-Fernandez A, Borg E, *et al.* Mucins MUC5B and MUC5AC in distal airways and honeycomb spaces: comparison among idiopathic pulmonary fibrosis/usual interstitial pneumonia, fibrotic nonspecific interstitial pneumonitis, and control lungs. *Am J Respir Crit Care Med* 2016; 193: 462–464.

353 Yang IV, Fingerlin TE, Evans CM, *et al.* MUC5B and idiopathic pulmonary fibrosis. *Ann Am Thorac Soc* 2015; 12: Suppl. 2, S193–S199.

354 Horimasu Y, Ohshimo S, Bonella F, *et al.* MUC5B promoter polymorphism in Japanese patients with idiopathic pulmonary fibrosis. *Respirology* 2015; 20: 439–444.

355 Borie R, Kannengiesser C, Antoniou K, *et al.* European Respiratory Society statement on familial pulmonary fibrosis. *Eur Respir J* 2023; 61: 2201383.

356 Cutting CC, Bowman WS, Dao N, *et al.* Family history of pulmonary fibrosis predicts worse survival in patients with interstitial lung disease. *Chest* 2021; 159: 1913–1921.

357 Fatumo S, Chikowore T, Choudhury A, *et al.* A roadmap to increase diversity in genomic studies. *Nat Med* 2022; 28: 243–250.

358 Newton CA, Oldham JM, Applegate C, *et al.* The role of genetic testing in pulmonary fibrosis: a perspective from the pulmonary fibrosis foundation genetic testing work group. *Chest* 2022; 162: 394–405.

359 Zhang D, Povysil G, Newton CA, *et al.* Genome-wide enrichment of TERT rare variants in idiopathic pulmonary fibrosis patients of Latino ancestry. *Am J Respir Crit Care Med* 2022; 206: 903–905.

360 Adegunsoye A, Freiheit E, White EN, *et al.* Evaluation of pulmonary fibrosis outcomes by race and ethnicity in US adults. *JAMA Netw Open* 2023; 6: e232427.

361 Adams TS, Schupp JC, Poli S, *et al.* Single-cell RNA-seq reveals ectopic and aberrant lung-resident cell populations in idiopathic pulmonary fibrosis. *Sci Adv* 2020; 6: eaba1983.

362 Habermann AC, Gutierrez AJ, Bui LT, *et al.* Single-cell RNA sequencing reveals profibrotic roles of distinct epithelial and mesenchymal lineages in pulmonary fibrosis. *Sci Adv* 2020; 6: eaba1972.

363 Furusawa H, Cardwell JH, Okamoto T, *et al.* Chronic hypersensitivity pneumonitis, an interstitial lung disease with distinct molecular signatures. *Am J Respir Crit Care Med* 2020; 202: 1430–1444.

364 Selman M, Pardo A, Barrera L, *et al.* Gene expression profiles distinguish idiopathic pulmonary fibrosis from hypersensitivity pneumonitis. *Am J Respir Crit Care Med* 2006; 173: 188–198.

365 Kim SY, Diggans J, Pankratz D, *et al.* Classification of usual interstitial pneumonia in patients with interstitial lung disease: assessment of a machine learning approach using high-dimensional transcriptional data. *Lancet Respir Med* 2015; 3: 473–482.

366 Raghu G, Flaherty KR, Lederer DJ, *et al.* Use of a molecular classifier to identify usual interstitial pneumonia in conventional transbronchial lung biopsy samples: a prospective validation study. *Lancet Respir Med* 2019; 7: 487–496.

367 Richeldi L, Scholand MB, Lynch DA, *et al.* Utility of a molecular classifier as a complement to high-resolution computed tomography to identify usual interstitial pneumonia. *Am J Respir Crit Care Med* 2021; 203: 211–220.

368 Lasky JA, Case A, Unterman A, *et al.* The impact of the Envisia Genomic Classifier in the diagnosis and management of patients with idiopathic pulmonary fibrosis. *Ann Am Thorac Soc* 2022; 19: 916–924.

369 Chaudhary S, Weigt SS, Ribeiro Neto ML, *et al.* Interstitial lung disease progression after genomic usual interstitial pneumonia testing. *Eur Respir J* 2023; 61: 2201245.

370 Bowman WS, Echt GA, Oldham JM. Biomarkers in progressive fibrosing interstitial lung disease: optimizing diagnosis, prognosis, and treatment response. *Front Med* 2021; 8: 680997.

371 Yang IV, Luna LG, Cotter J, *et al.* The peripheral blood transcriptome identifies the presence and extent of disease in idiopathic pulmonary fibrosis. *PLoS One* 2012; 7: e37708.

372 Herazo-Maya JD, Noth I, Duncan SR, *et al.* Peripheral blood mononuclear cell gene expression profiles predict poor outcome in idiopathic pulmonary fibrosis. *Sci Transl Med* 2013; 5: 205ra136.

373 Herazo-Maya JD, Sun J, Molyneaux PL, *et al.* Validation of a 52-gene risk profile for outcome prediction in patients with idiopathic pulmonary fibrosis: an international, multicentre, cohort study. *Lancet Respir Med* 2017; 5: 857–868.

374 Wang Y, Yella J, Chen J, *et al.* Unsupervised gene expression analyses identify IPF-severity correlated signatures, associated genes and biomarkers. *BMC Pulm Med* 2017; 17: 133.

375 Cecchini MJ, Hosein K, Howlett CJ, *et al.* Comprehensive gene expression profiling identifies distinct and overlapping transcriptional profiles in non-specific interstitial pneumonia and idiopathic pulmonary fibrosis. *Respir Res* 2018; 19: 153.

376 Zhang N, Guo Y, Wu C, *et al.* Identification of the molecular subgroups in idiopathic pulmonary fibrosis by gene expression profiles. *Comput Math Methods Med* 2021; 2021: 7922594.

377 Liu Y, Xu C, Gao W, *et al.* Transcriptome classification reveals molecular subgroups in idiopathic pulmonary fibrosis. *Genet Res* 2022; 2022: 7448481.

Downloaded from https://publications.ersnet.org on October 19, 2026 by guest. Please see licensing information on first page for reuse rights.

378 Konigsberg IR, Borie R, Walts AD, *et al.* Molecular signatures of idiopathic pulmonary fibrosis. *Am J Respir Cell Mol Biol* 2021; 65: 430–441.
379 Ruan P, Todd JL, Zhao H, *et al.* Integrative multi-omics analysis reveals novel idiopathic pulmonary fibrosis endotypes associated with disease progression. *Respir Res* 2023; 24: 141.
380 Tsukui T, Sun KH, Wetter JB, *et al.* Collagen-producing lung cell atlas identifies multiple subsets with distinct localization and relevance to fibrosis. *Nat Commun* 2020; 11: 1920.
381 Jia M, Rosas L, Kapetanaki MG, *et al.* Early events marking lung fibroblast transition to profibrotic state in idiopathic pulmonary fibrosis. *Respir Res* 2023; 24: 116.
382 Liu X, Dai K, Zhang X, *et al.* Multiple fibroblast subtypes contribute to matrix deposition in pulmonary fibrosis. *Am J Respir Cell Mol Biol* 2023; 69: 45–56.
383 Ghosh AJ, Hobbs BD, Yun JH, *et al.* Lung tissue shows divergent gene expression between chronic obstructive pulmonary disease and idiopathic pulmonary fibrosis. *Respir Res* 2022; 23: 97.
384 McEachern MJ, Krauskopf A, Blackburn EH. Telomeres and their control. *Annu Rev Genet* 2000; 34: 331–358.
385 Lim CJ, Cech TR. Shaping human telomeres: from shelterin and CST complexes to telomeric chromatin organization. *Nat Rev Mol Cell Biol* 2021; 22: 283–298.
386 Lee S, Islam MN, Boostanpour K, *et al.* Molecular programs of fibrotic change in aging human lung. *Nat Commun* 2021; 12: 6309.
387 Adegunsoye A, Newton CA, Oldham JM, *et al.* Telomere length associates with chronological age and mortality across racially diverse pulmonary fibrosis cohorts. *Nat Commun* 2023; 14: 1489.
388 Stuart BD, Lee JS, Kozlitina J, *et al.* Effect of telomere length on survival in patients with idiopathic pulmonary fibrosis: an observational cohort study with independent validation. *Lancet Respir Med* 2014; 2: 557–565.
389 Newton CA, Zhang D, Oldham JM, *et al.* Telomere length and use of immunosuppressive medications in idiopathic pulmonary fibrosis. *Am J Respir Crit Care Med* 2019; 200: 336–347.
390 Snetselaar R, van Moorsel CHM, Kazemier KM, *et al.* Telomere length in interstitial lung diseases. *Chest* 2015; 148: 1011–1018.
391 Planas-Cerezales L, Arias-Salgado EG, Buendia-Roldán I, *et al.* Predictive factors and prognostic effect of telomere shortening in pulmonary fibrosis. *Respirology* 2019; 24: 146–153.
392 Dai J, Cai H, Li H, *et al.* Association between telomere length and survival in patients with idiopathic pulmonary fibrosis. *Respirology* 2015; 20: 947–952.
393 Liu S, Chung MP, Ley B, *et al.* Peripheral blood leucocyte telomere length is associated with progression of interstitial lung disease in systemic sclerosis. *Thorax* 2021; 76: 1186–1192.
394 Natalini JG, England BR, Baker JF, *et al.* Associations between shortened telomeres and rheumatoid arthritis-associated interstitial lung disease among U.S. veterans. *Respir Med* 2022; 201: 106943.
395 Zhang D, Adegunsoye A, Oldham JM, *et al.* Telomere length and immunosuppression in non-idiopathic pulmonary fibrosis interstitial lung disease. *Eur Respir J* 2023; 62: 2300441.
396 Ley B, Liu S, Elicker BM, *et al.* Telomere length in patients with unclassifiable interstitial lung disease: a cohort study. *Eur Respir J* 2020; 56: 2000268.
397 Adegunsoye A, Morisset J, Newton CA, *et al.* Leukocyte telomere length and mycophenolate therapy in chronic hypersensitivity pneumonitis. *Eur Respir J* 2021; 57: 2202872.
398 Newton CA, Kozlitina J, Lines JR, *et al.* Telomere length in patients with pulmonary fibrosis associated with chronic lung allograft dysfunction and post-lung transplantation survival. *J Heart Lung Transplant* 2017; 36: 845–853.
399 Popescu I, Mannem H, Winters SA, *et al.* Impaired cytomegalovirus immunity in idiopathic pulmonary fibrosis lung transplant recipients with short telomeres. *Am J Respir Crit Care Med* 2019; 199: 362–376.
400 Hannan SJ, Iasella CJ, Sutton RM, *et al.* Lung transplant recipients with telomere-mediated pulmonary fibrosis have increased risk for hematologic complications. *Am J Transplant* 2023; 23: 1590–1602.
401 Courtwright AM, Lamattina AM, Takahashi M, *et al.* Shorter telomere length following lung transplantation is associated with clinically significant leukopenia and decreased chronic lung allograft dysfunction-free survival. *ERJ Open Res* 2020; 6: 00003-2020.
402 Kondoh Y, Makino S, Ogura T, *et al.* 2020 guide for the diagnosis and treatment of interstitial lung disease associated with connective tissue disease. *Respir Investig* 2021; 59: 709–740.
403 Romero-Bueno F, Diaz Del Campo P, Trallero-Araguas E, *et al.* Recommendations for the treatment of anti-melanoma differentiation-associated gene 5-positive dermatomyositis-associated rapidly progressive interstitial lung disease. *Semin Arthritis Rheum* 2020; 50: 776–790.
404 Sato S, Kuwana M, Fujita T, *et al.* Anti-CADM-140/MDA5 autoantibody titer correlates with disease activity and predicts disease outcome in patients with dermatomyositis and rapidly progressive interstitial lung disease. *Mod Rheumatol* 2013; 23: 496–502.
405 Matsushita T, Mizumaki K, Kano M, *et al.* Antimelanoma differentiation-associated protein 5 antibody level is a novel tool for monitoring disease activity in rapidly progressive interstitial lung disease with dermatomyositis. *Br J Dermatol* 2017; 176: 395–402.

Downloaded from https://publications.ersnet.org on October 19, 2026 by guest. Please see licensing information on first page for reuse rights.

406 Fischer A, Pfalzgraf FJ, Feghali-Bostwick CA, *et al.* Anti-th/to-positivity in a cohort of patients with idiopathic pulmonary fibrosis. *J Rheumatol* 2006; 33: 1600–1605.

407 Lee JS, Kim EJ, Lynch KL, *et al.* Prevalence and clinical significance of circulating autoantibodies in idiopathic pulmonary fibrosis. *Respir Med* 2013; 107: 249–255.

408 Moua T, Maldonado F, Decker PA, *et al.* Frequency and implication of autoimmune serologies in idiopathic pulmonary fibrosis. *Mayo Clin Proc* 2014; 89: 319–326.

409 Adegunsoye A, Oldham JM, Demchuk C, *et al.* Predictors of survival in coexistent hypersensitivity pneumonitis with autoimmune features. *Respir Med* 2016; 114: 53–60.

410 Buendia-Roldán I, Santiago-Ruiz L, Perez-Rubio G, *et al.* A major genetic determinant of autoimmune diseases is associated with the presence of autoantibodies in hypersensitivity pneumonitis. *Eur Respir J* 2020; 56: 1901380.

411 Guo YP, Wang CG, Liu X, *et al.* The prevalence of antinuclear antibodies in the general population of China: a cross-sectional study. *Curr Ther Res Clin Exp* 2014; 76: 116–119.

412 Nisihara R, Kubis MM, Rodrigues PC, *et al.* Antinuclear antibodies and rheumatoid factor positivity in healthy elderly adults: a cross-sectional study in 336 individuals. *J Am Geriatr Soc* 2013; 61: 2044–2046.

413 Karabey M, Kaya H, Ceylan A, *et al.* The effect of the pandemic on autoantibody rates in the general population. *Arch Rheumatol* 2024; 39: 541–548.

414 Fukihara J, Kondoh Y. COVID-19 and interstitial lung diseases: a multifaceted look at the relationship between the two diseases. *Respir Investig* 2023; 61: 601–617.

415 David P, Sinha S, Iqbal K, *et al.* MDA5-autoimmunity and interstitial pneumonitis contemporaneous with the COVID-19 pandemic (MIP-C). *EBioMedicine* 2024; 104: 105136.

416 Gagiannis D, Steinestel J, Hackenbroch C, *et al.* Clinical, serological, and histopathological similarities between severe COVID-19 and acute exacerbation of connective tissue disease-associated interstitial lung disease (CTD-ILD). *Front Immunol* 2020; 11: 587517.

417 De Giacomi F, Andreano A, Faverio P, *et al.* Utility of precipitating antibody testing in the diagnostic evaluation of chronic hypersensitivity pneumonia. *Sarcoidosis Vasc Diffuse Lung Dis* 2017; 34: 149–155.

418 Morell F, Villar A, Montero MA, *et al.* Chronic hypersensitivity pneumonitis in patients diagnosed with idiopathic pulmonary fibrosis: a prospective case-cohort study. *Lancet Respir Med* 2013; 1: 685–694.

419 Lacasse Y, Selman M, Costabel U, *et al.* Clinical diagnosis of hypersensitivity pneumonitis. *Am J Respir Crit Care Med* 2003; 168: 952–958.

420 Fenoglio CM, Reboux G, Sudre B, *et al.* Diagnostic value of serum precipitins to mould antigens in active hypersensitivity pneumonitis. *Eur Respir J* 2007; 29: 706–712.

421 Maher TM, Oballa E, Simpson JK, *et al.* An epithelial biomarker signature for idiopathic pulmonary fibrosis: an analysis from the multicentre PROFILE cohort study. *Lancet Respir Med* 2017; 5: 946–955.

422 Alqalyoobi S, Adegunsoye A, Linderholm A, *et al.* Circulating plasma biomarkers of progressive interstitial lung disease. *Am J Respir Crit Care Med* 2020; 201: 250–253.

423 Organ LA, Duggan AR, Oballa E, *et al.* Biomarkers of collagen synthesis predict progression in the PROFILE idiopathic pulmonary fibrosis cohort. *Respir Res* 2019; 20: 148.

424 Jenkins RG, Simpson JK, Saini G, *et al.* Longitudinal change in collagen degradation biomarkers in idiopathic pulmonary fibrosis: an analysis from the prospective, multicentre PROFILE study. *Lancet Respir Med* 2015; 3: 462–472.

425 Doubková M, Karpíšek M, Mazoch J, *et al.* Prognostic significance of surfactant protein A, surfactant protein D, Clara cell protein 16, S100 protein, trefoil factor 3, and prostatic secretory protein 94 in idiopathic pulmonary fibrosis, sarcoidosis, and chronic pulmonary obstructive disease. *Sarcoidosis Vasc Diffuse Lung Dis* 2016; 33: 224–234.

426 Wakamatsu K, Nagata N, Kumazoe H, *et al.* Prognostic value of serial serum KL-6 measurements in patients with idiopathic pulmonary fibrosis. *Respir Investig* 2017; 55: 16–23.

427 Stock CJW, Bray WG, Kouranos V, *et al.* Serum C-reactive protein is associated with earlier mortality across different interstitial lung diseases. *Respirology* 2023; 29: 228–234.

428 Khan FA, Stewart I, Saini G, *et al.* A systematic review of blood biomarkers with individual participant data meta-analysis of matrix metalloproteinase-7 in idiopathic pulmonary fibrosis. *Eur Respir J* 2021; 59: 2101612.

429 Adegunsoye A, Alqalyoobi S, Linderholm A, *et al.* Circulating plasma biomarkers of survival in antifibrotic-treated patients with idiopathic pulmonary fibrosis. *Chest* 2020; 158: 1526–1534.

430 Prasse A, Probst C, Bargagli E, *et al.* Serum CC-chemokine ligand 18 concentration predicts outcome in idiopathic pulmonary fibrosis. *Am J Respir Crit Care Med* 2009; 179: 717–723.

431 Molyneaux PL, Fahy WA, Byrne AJ, *et al.* CYFRA 21-1 predicts progression in idiopathic pulmonary fibrosis: a prospective longitudinal analysis of the PROFILE cohort. *Am J Respir Crit Care Med* 2022; 205: 1440–1448.

432 Jenkins GN, Noth I, Selman M, *et al.* Effects of nintedanib on markers of epithelial damage in subjects with IPF: data from the INMARK trial. *Eur Respir J* 2020; 56: Suppl. 64, 5187.

Downloaded from https://publications.ersnet.org on October 19, 2026 by guest. Please see licensing information on first page for reuse rights.

433 Kass DJ, Nouraie M, Glassberg MK, *et al.* Comparative profiling of serum protein biomarkers in rheumatoid arthritis-associated interstitial lung disease and idiopathic pulmonary fibrosis. *Arthritis Rheumatol* 2020; 72: 409–419.

434 Todd JL, Neely ML, Overton R, *et al.* Peripheral blood proteomic profiling of idiopathic pulmonary fibrosis biomarkers in the multicentre IPF-PRO Registry. *Respir Res* 2019; 20: 227.

435 Bowman WS, Newton CA, Linderholm AL, *et al.* Proteomic biomarkers of progressive fibrosing interstitial lung disease: a multicentre cohort analysis. *Lancet Respir Med* 2022; 10: 593–602.

436 Van Ballaer V, Dubbeldam A, Muscogiuri E, *et al.* Impact of ultra-high-resolution imaging of the lungs on perceived diagnostic image quality using photon-counting CT. *Eur Radiol* 2024; 34: 1895–1904.

437 Inoue A, Johnson TF, White D, *et al.* Estimating the clinical impact of photon-counting-detector CT in diagnosing usual interstitial pneumonia. *Invest Radiol* 2022; 57: 734–741.

438 Gaillandre Y, Duhamel A, Flohr T, *et al.* Ultra-high resolution CT imaging of interstitial lung disease: impact of photon-counting CT in 112 patients. *Eur Radiol* 2023; 33: 5528–5539.

439 Fletcher JG, Inoue A, Bratt A, *et al.* Photon-counting CT in thoracic imaging: early clinical evidence and incorporation into clinical practice. *Radiology* 2024; 310: e231986.

440 Hariri LP, Adams DC, Wain JC, *et al.* Endobronchial optical coherence tomography for low-risk microscopic assessment and diagnosis of idiopathic pulmonary fibrosis *in vivo*. *Am J Respir Crit Care Med* 2018; 197: 949–952.

441 Nandy S, Berigei SR, Keyes CM, *et al.* Polarization-sensitive endobronchial optical coherence tomography for microscopic imaging of fibrosis in interstitial lung disease. *Am J Respir Crit Care Med* 2022; 206: 905–910.

442 Nandy S, Raphaely RA, Muniappan A, *et al.* Diagnostic accuracy of endobronchial optical coherence tomography for the microscopic diagnosis of usual interstitial pneumonia. *Am J Respir Crit Care Med* 2021; 204: 1164–1179.

443 Berigei SR, Nandy S, Yamamoto S, *et al.* Microscopic small airway abnormalities identified in early idiopathic pulmonary fibrosis *in vivo* using endobronchial optical coherence tomography. *Am J Respir Crit Care Med* 2024; 210: 473–483.

444 Lukey PT, Harrison SA, Yang S, *et al.* A randomised, placebo-controlled study of omipalisib (PI3K/mTOR) in idiopathic pulmonary fibrosis. *Eur Respir J* 2019; 53: 1801992.

445 Montesi SB, Izquierdo-Garcia D, Désogère P, *et al.* Type I collagen-targeted positron emission tomography imaging in idiopathic pulmonary fibrosis: first-in-human studies. *Am J Respir Crit Care Med* 2019; 200: 258–261.

446 Maher TM, Simpson JK, Porter JC, *et al.* A positron emission tomography imaging study to confirm target engagement in the lungs of patients with idiopathic pulmonary fibrosis following a single dose of a novel inhaled $\alpha v\beta 6$ integrin inhibitor. *Respir Res* 2020; 21: 75.

447 Derlin T, Jaeger B, Jonigk D, *et al.* Clinical molecular imaging of pulmonary CXCR4 expression to predict outcome of pirfenidone treatment in idiopathic pulmonary fibrosis. *Chest* 2021; 159: 1094–1106.

448 Mooney JJ, Jacobs S, Lefebvre EA, *et al.* Bexotegrast shows dose-dependent integrin $\alpha_v\beta_6$ receptor occupancy in lungs of participants with idiopathic pulmonary fibrosis: a phase 2, open-label clinical trial. *Ann Am Thorac Soc* 2025; 22: 350–358.

449 Montesi SB, Cosgrove GP, Turner SM, *et al.* Dual $\alpha_v\beta_6$ and $\alpha_v\beta_1$ inhibition over 12 weeks reduces active type 1 collagen deposition in individuals with idiopathic pulmonary fibrosis: a phase 2, double-blind, placebo-controlled clinical trial. *Am J Respir Crit Care Med* 2025; 211: 1229–1240.

Downloaded from https://publications.ersnet.org on October 19, 2026 by guest. Please see licensing information on first page for reuse rights.